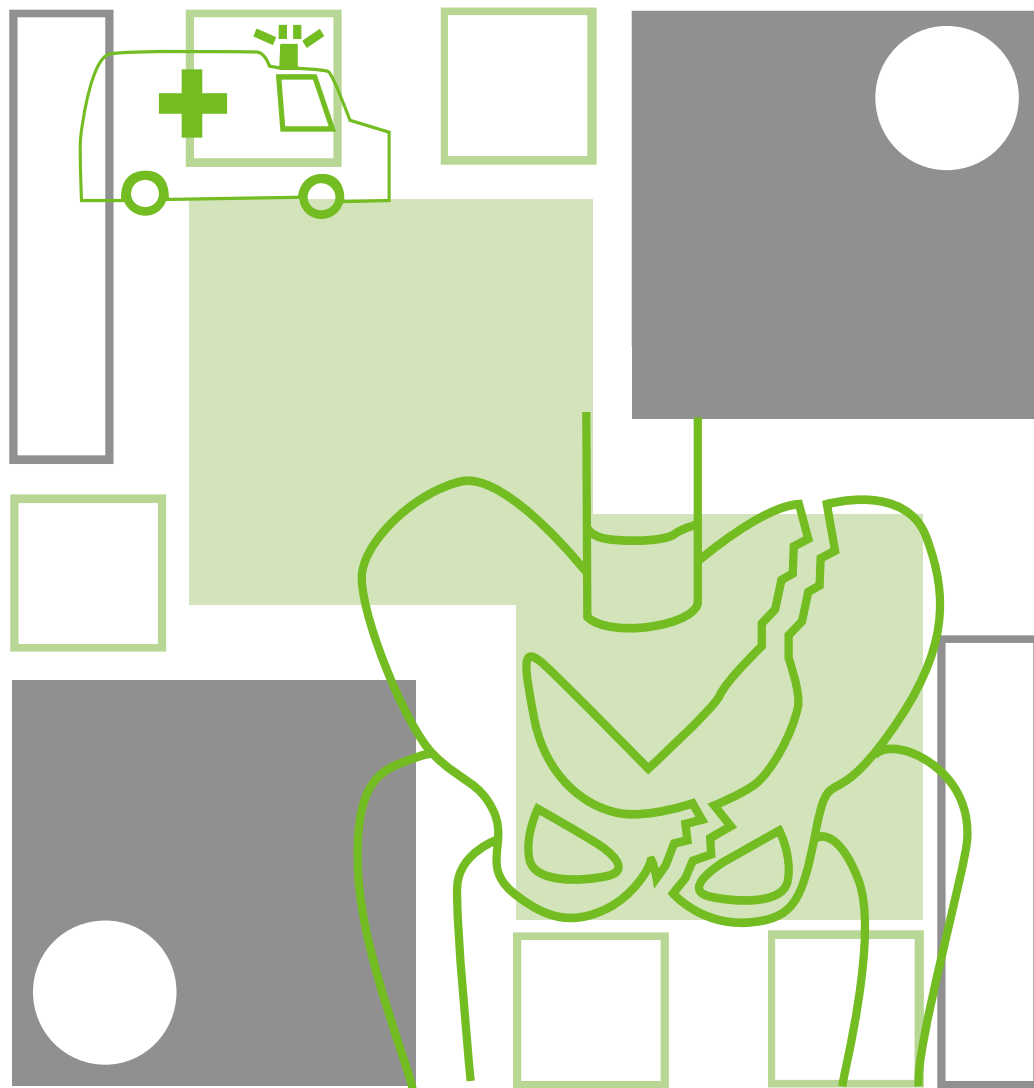


■ ■ Management of haemodynamically unstable patients with a Pelvic Fracture



Suggested citation:

Dr Martin Heetveld 2007, *The Management of Haemodynamically Unstable Patients with a Pelvic Fracture*, NSW Institute of Trauma and Injury Management.

Author

Dr Martin Heetveld, Trauma Fellow, Trauma Service, Liverpool Hospital

Editorial team

NSW ITIM Clinical Guidelines Committee

Dr Ian Harris, Director of Orthopaedics, Liverpool Hospital

Ms Kathleen Peters (RN), Case Manager, Trauma Service, Liverpool Hospital

Dr Glen Schlaphoff, Director of Radiology, Liverpool Hospital

Assoc. Prof. Michael Sugrue, Trauma Director, Trauma Service, Liverpool Hospital

Ms Joan Lynch (RN), Project Manager, Trauma Service, Liverpool Hospital

Mr Glenn Sisson (RN), Trauma Clinical Education Manager, NSW ITIM

This work is copyright. It may be reproduced in whole or in part for study training purposes subject to the inclusion of an acknowledgement of the source. It may not be reproduced for commercial usage or sale. Reproduction for purposes other than those indicated above requires written permission from the NSW Institute of Trauma and Injury Management.

© NSW Institute of Trauma and Injury Management

SHPN (TI) 070026

ISBN 978-1-74187-143-5

For further copies contact:

NSW Institute of Trauma and Injury Management

PO Box 6314, North Ryde, NSW 2113

Ph: (02) 9887 5726

or can be downloaded from the NSW ITIM website

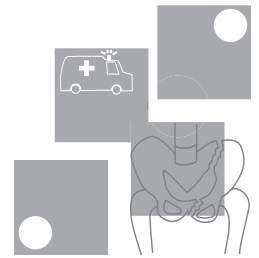
<http://www.itim.nsw.gov.au>

or the

NSW Health website <http://www.health.nsw.gov.au>

January 2007

Important notice!



'The Management of Haemodynamically Unstable Patients with a Pelvic Fracture' clinical practice guidelines are aimed at assisting clinicians in informed medical decision-making. They are not intended to replace decision-making. The authors appreciate the heterogeneity of the patient population and the signs and symptoms they may present with and the need to often modify management in light of a patient's co-morbidities.

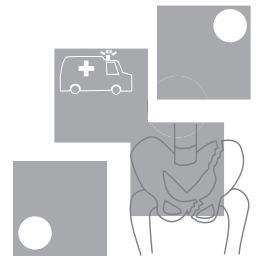
The guidelines are intended to provide a general guide to the management of specified injuries. The guidelines are not a definitive statement on the correct procedures, rather they constitute a general guide to be followed subject to the clinicians judgement in each case.

The information provided is based on the best available information at the time of writing, which is December 2003. These guidelines will therefore be updated every five years and consider new evidence as it becomes available.

These guidelines are intended for use in adults only.

All guidelines regarding pre-hospital care should be read and considered in conjunction with NSW Ambulance Service protocols.

Contents



Algorithm 1 ::

Management of the Haemodynamically Unstable Patient with a Pelvic Fracture with Angiography Services available1

Algorithm 2 ::

Management of the Haemodynamically Unstable Patient with a Pelvic Fracture without Angiography Services available2

Summary of guidelines.....3

1 Introduction.....9

2 Methods.....12

3 How to determine the source of bleeding in haemodynamically unstable pelvic fracture patients?14

4 How to control pelvic with or without associated intraabdominal bleeding?.....16

5 What is the optimal angiography and embolisation technique?22

6 How to optimally mechanically stabilise the pelvis?22

Evidence table.....28

Appendices

APPENDIX A ::

Pelvic sheeting.....36

References37

List of tables

Table 1. Levels of evidence12

List of figures

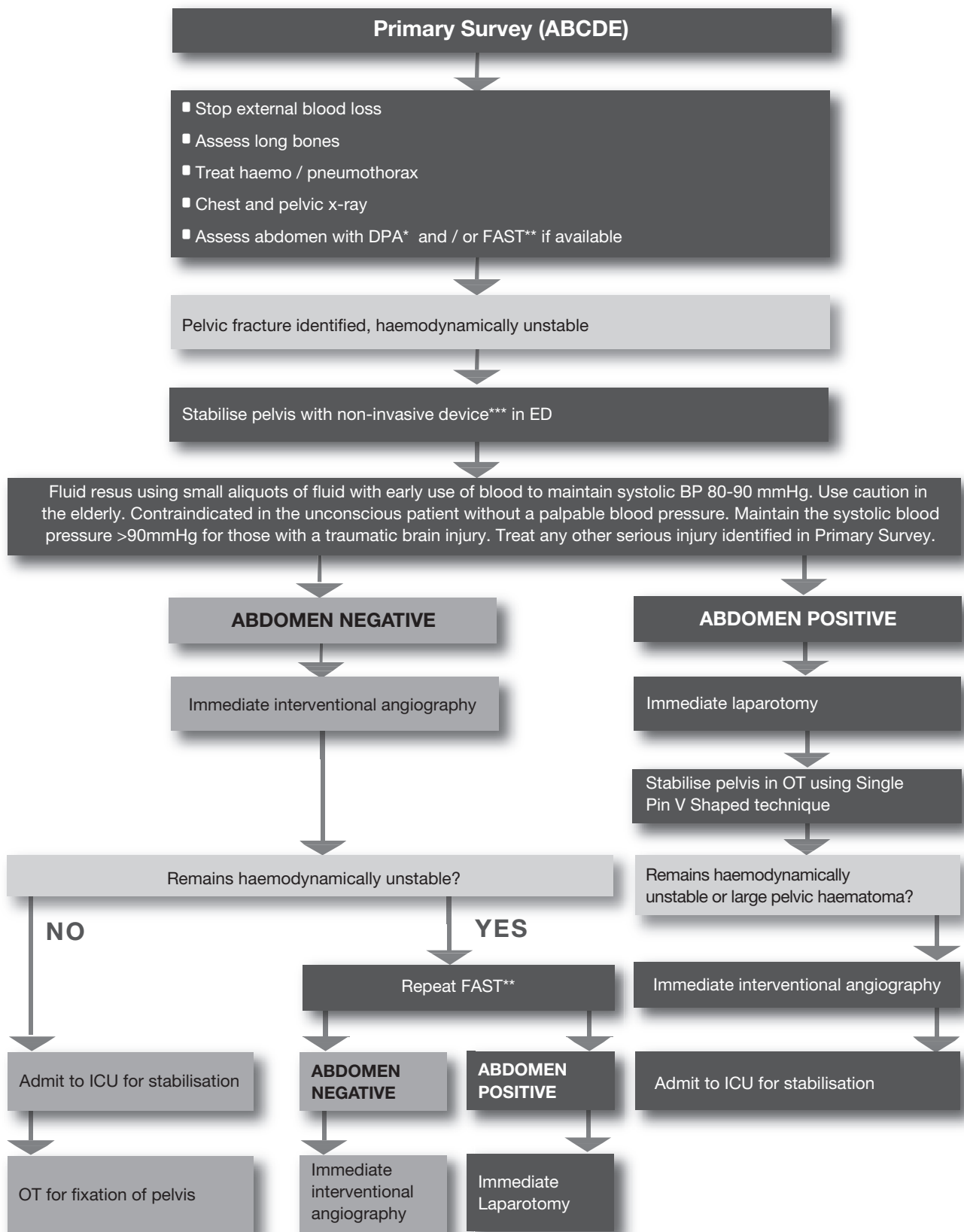
Figure 1. The Young-Burgess classification.....10

Figure 2. The proximity of the arteries in relation to the pelvis15

Figure 3. Type of pelvic fractures that benefit from stabilisation25

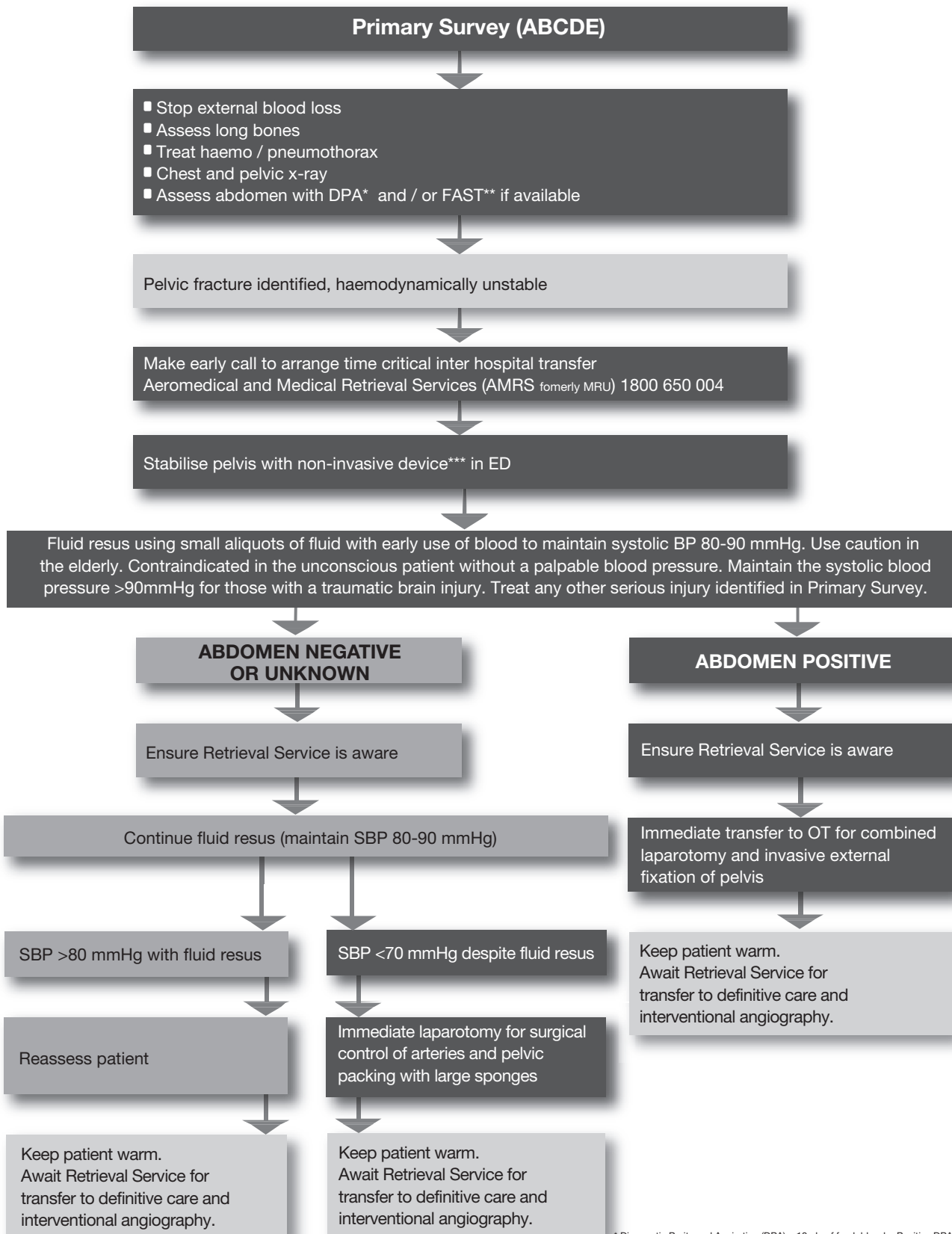
Algorithm 1 :: Management of the Haemodynamically Unstable Patient with a Pelvic Fracture with Angiography Services available

Management of the Haemodynamically Unstable Patient with a Pelvic Fracture **with** Angiography Services available

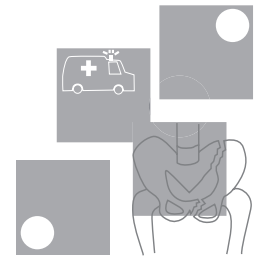


Algorithm 2 :: Management of the Haemodynamically Unstable Patient with a Pelvic Fracture without Angiography Services available

Management of the Haemodynamically Unstable Patient with a Pelvic Fracture **without** Angiography Services available



Summary of guidelines



How to determine the source of bleeding in haemodynamically unstable pelvic fracture patients?

GUIDELINE	LEVEL OF EVIDENCE
When the haemodynamically unstable patient enters the resuscitation room, a primary survey with full exposure takes place. Carefully inspect for external bleeding sources and examine the long bones. A supine chest x-ray and pelvic X-ray must be obtained within ten minutes of arrival. The CXR will identify a large haemothorax. If the pelvic x-ray shows a pelvic fracture, the remaining two sites of significant bleeding are the abdomen and the pelvic retroperitoneum.	III-3
The probability of associated intraabdominal bleeding with a major pelvic fracture is 32%. The options for assessing intraabdominal bleeding are: Diagnostic Peritoneal Aspiration (DPA) and / or Focused Abdominal Sonography in Trauma (FAST). Both should be completed within 30 minutes of the patient's arrival.	III-3
DPA is a reliable diagnostic test for determining frank blood in the abdominal cavity. The aspiration is positive in the presence of >10 ml of frank blood.	III-3
FAST is a good alternative diagnostic modality for evaluating free fluid in the presence of a pelvic fracture. Most frequently FAST is positive in the right upper quadrant. The suprapubic view is unreliable in pelvic fracture patients. If practical, FAST should be repeated to increase sensitivity.	III-2
When external sources, long bones, intrathoracic injury and intra-abdominal injury do not account for the hypotension in a haemodynamically unstable patient with a major pelvic fracture, pelvic arterial bleeding must be evaluated. The patient should go for immediate angiography.	III-3
In the presence of a pelvic fracture and haemodynamic instability, pelvic arterial bleeding must be evaluated even if other sources of haemorrhage have been identified.	IV
In the rural or urban environment where DPA or FAST is not available, identification of the source of bleeding is reliant on the method of exclusion. Upon exclusion of the other four sources of bleeding and in light of continuing haemodynamic instability it must be assumed that the patient has intraabdominal bleeding until proven otherwise.	Consensus

How to control pelvic bleeding with or without associated intraabdominal bleeding?

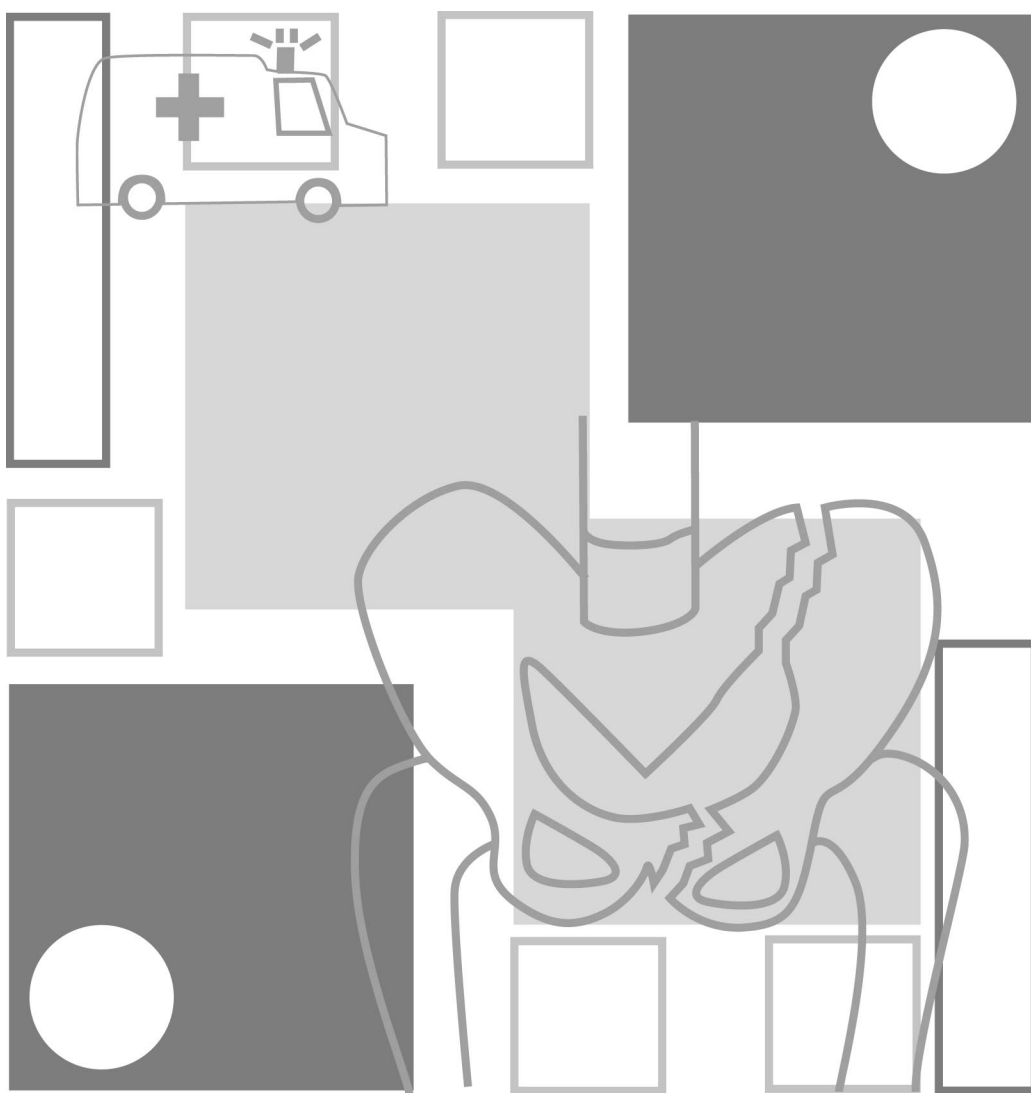
GUIDELINE	LEVEL OF EVIDENCE
If intra-abdominal bleeding has been excluded by DPA and / or FAST, immediate angiography and embolisation is warranted. Transfer to the angiography suite should take place within 45 minutes of the patient's arrival. Close monitoring, ongoing resuscitation and re-assessment of an intra-abdominal bleeding source utilising FAST and / or clinical parameters are mandatory in the angiography suite.	III-3
Haemodynamically unstable patients with pelvic fractures should be managed with early non-invasive external stabilisation to aid in controlling small venous and cancellous bone bleeding. In the case of a vertical shear type pelvic fracture, supplementary femoral pin traction is necessary on the affected side. External stabilisation does not control arterial bleeding.	III-1
If laparotomy is warranted, a non-invasive or invasive external stabilisation device should be placed concomitantly with laparotomy in the operating theatre. If angiography is warranted, a non-invasive external stabilisation device should be placed prior to transfer in the resuscitation room.	IV
If intra-abdominal bleeding has been determined by DPA and / or FAST, immediate laparotomy is warranted. Concomitant intestinal perforation should be dealt with in a damage control fashion if necessary.	III-3
If at laparotomy, performed for intraabdominal haemorrhage, there is a freely bleeding ruptured pelvic haematoma, packing and immediate transfer to angiography is preferable. Where angiography is not available or the patient is too unstable (blood pressure unable to be restored above 70 mmHg), the haematoma should be evacuated, the internal iliac arteries bilaterally ligated and the pelvis packed.	IV
In the situation of exsanguination at presentation, with little or no response to fluid resuscitation, immediate operation is the only life saving option: Laparotomy with surgical ligation of bleeding arteries, pelvic packing with large sponges and stabilisation of the pelvis.	IV
Internal fixation of major pelvic fractures is contra-indicated in haemodynamically unstable patients.	IV
In the situation where angiography services are not available, management is determined by the degree of haemodynamic instability. In the presence of reasonable haemodynamic stability (SBP>80mmhg), the pelvis should be non-invasively externally stabilised and Retrieval Services should be contacted as a matter of urgency. If the systolic blood pressure drops below 80-90mmHg, small aliquots of fluid (100-200mls) may administered. If the blood pressure becomes increasingly unstable (SBP<80mmHg) and cannot be maintained with small boluses of fluid, immediate laparotomy with surgical ligation of bleeding arteries, pelvic packing with large sponges and invasive external stabilisation of the pelvis is the only life saving option available. An unstable patient should not be transferred where surgical services are available until surgical haemostasis has been achieved.	Consensus

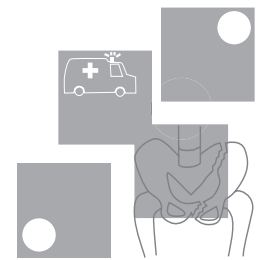
What is the optimal angiography and embolisation technique?

GUIDELINE	LEVEL OF EVIDENCE
If a major pelvic fracture is seen on the initial pelvic x-ray in the haemodynamically unstable patient, the interventional radiologist and nursing staff should be notified immediately. It is critically important that the general surgeon coordinates care between emergency clinicians, interventional radiologist, orthopaedic surgeon, intensive care specialist, nursing and blood bank.	IV
Angiography should be performed as soon as the abdomen has been cleared as a source of bleeding or within 90 minutes of presentation. A femoral approach is preferred, but a left brachial puncture may be needed in patients in which femoral approach fails.	IV
Using 4 or 5 Fr catheters, angiography begins with a midstream abdominal flush to reassess any abdominal bleeding. A pelvis flush is then performed at aortic bifurcation level. An arterial haemorrhage requiring embolisation should present itself at the pelvis midstream flush.	III-3
Any sites of contrast extravasation, false aneurysms and occlusion of the mainstem internal iliac artery warrant embolisation. Vasospasm due to major haemorrhage may obscure bleeding distal to the spasm.	IV
Non-selective embolisation of main arteries, such as the internal iliac arteries or their first divisional branches should be performed with steel coils. Steel coils are also preferred for selective embolisation of bleeding branches. In patients with multiple distal, small branch bleeding sites a shower of gelfoam slurry can be utilised.	IV
Selective embolisation of smaller branches should be used judiciously. If respiratory or hemodynamic instability increases during angiography, non-selective bilateral embolisation of the internal iliac arteries with steel coils should be performed. Complete occlusion of the internal iliac artery is an acceptable alternative to exsanguination.	IV
Once a vessel is embolised for distal branch extravasation, the potential collateral vessels of both internal iliac arteries should be evaluated to identify additional supply to the injured vascular bed. Completion angiography is necessary to document cessation of bleeding.	IV

How to optimally mechanically stabilise the pelvis?

GUIDELINE	LEVEL OF EVIDENCE
Rotationally unstable APC types II and III, LC type III pelvic fractures benefit most from external stabilisation. If vertical instability is also present, such as in VS and combination type pelvic fractures, rotational stabilisation needs to be supplemented by skeletal traction on the injured side.	III-3
The optimal time-effective and safe pelvic external stabilisation device in the haemodynamically unstable patient is non-invasive. A bed sheet wrapped and clamped tightly around the pelvis is a good option. There are a variety of non-invasive proprietary devices available. The device should be applied so that it allows both laparotomy access and femoral artery access for angiography.	IV
Invasive anterior external fixation devices for rotational stabilisation should only be applied when non-invasive devices fail, interfere with procedures or if more time is needed until definitive internal fixation.	IV
The simplest effective form of invasive anterior external fixation consists of a single 5-mm Schantz pin on each side, connected to two radiolucent bridging bars in a triangular construct or a single radiolucent curved rod. The apex of the triangle or top of the curve of should be placed inferiorly in the midline of the pelvis, allowing laparotomy access and the patient to sit up.	III-3





1 Introduction

Mortality rates from pelvic fractures remain the greatest of any skeletal injury, with retroperitoneal haemorrhage representing the major potentially reversible issue. For clearer understanding, mortality reporting can be divided into three categories:

1. Overall mortality of pelvic fractures with and without haemodynamic instability, 2. Closed pelvic fractures with haemodynamic instability and 3. Open pelvic fractures.

Category 1

Overall pelvic fracture mortality is 16% (range 5-30%).¹⁻¹¹

Category 2

Closed pelvic fracture with haemodynamic instability mortality is 27% (range 10-42%).¹²⁻¹⁹

Category 3

Open pelvic fracture is a lethal injury with a reported 55% mortality (range 50-60%).^{2;4}

The pelvis possesses exceptional inherent strength and the major external force that is required to fracture a pelvis is also transferred to head, chest, abdomen, the genitourinary system and other skeletal structures. In the pelvis the close proximity of major arteries, veins and highly vascularised cancellous bone increase the risk of severe haemorrhage.²⁰ Varying degrees of venous and cancellous bone bleeding are present in all types of pelvic fractures.

Physical assessment is highly sensitive in determining the presence of fracture of the pelvis in a conscious and orientated patient. Findings warranting a plain pelvic X-ray are hip pain, groin pain, low back pain, tenderness to palpation over the pelvic girdle, obvious deformities and ecchymosis or abrasions around the pelvic area.²¹ To detect an unstable fracture pattern of the pelvic bones at physical examination springing of the pelvis is advocated, but unless one is experienced in pelvic fracture surgery, the sensitivity of pelvic springing is only 59% and is painful in the awake patient.²²

The most common mechanisms of pelvic fractures are motor vehicle accidents (57%), pedestrians hit by motor vehicles (18%), motorcycle accidents (9%), falls (9%) and crush injuries (4%).²³

Haemorrhage is the major contribution to mortality in 42% of pelvic trauma patients. Of these, 62% is due to pelvic haemorrhage and 38% is due to associated external, intrathoracic and intraabdominal haemorrhage sources.^{5-7;14;24;25} Non-haemorrhage causes of mortality from associated injuries are related to head injury (32%), followed by sepsis leading to multi-organ failure (14%), and cardio-respiratory failure (8%).^{2;5;6;14;25;26}

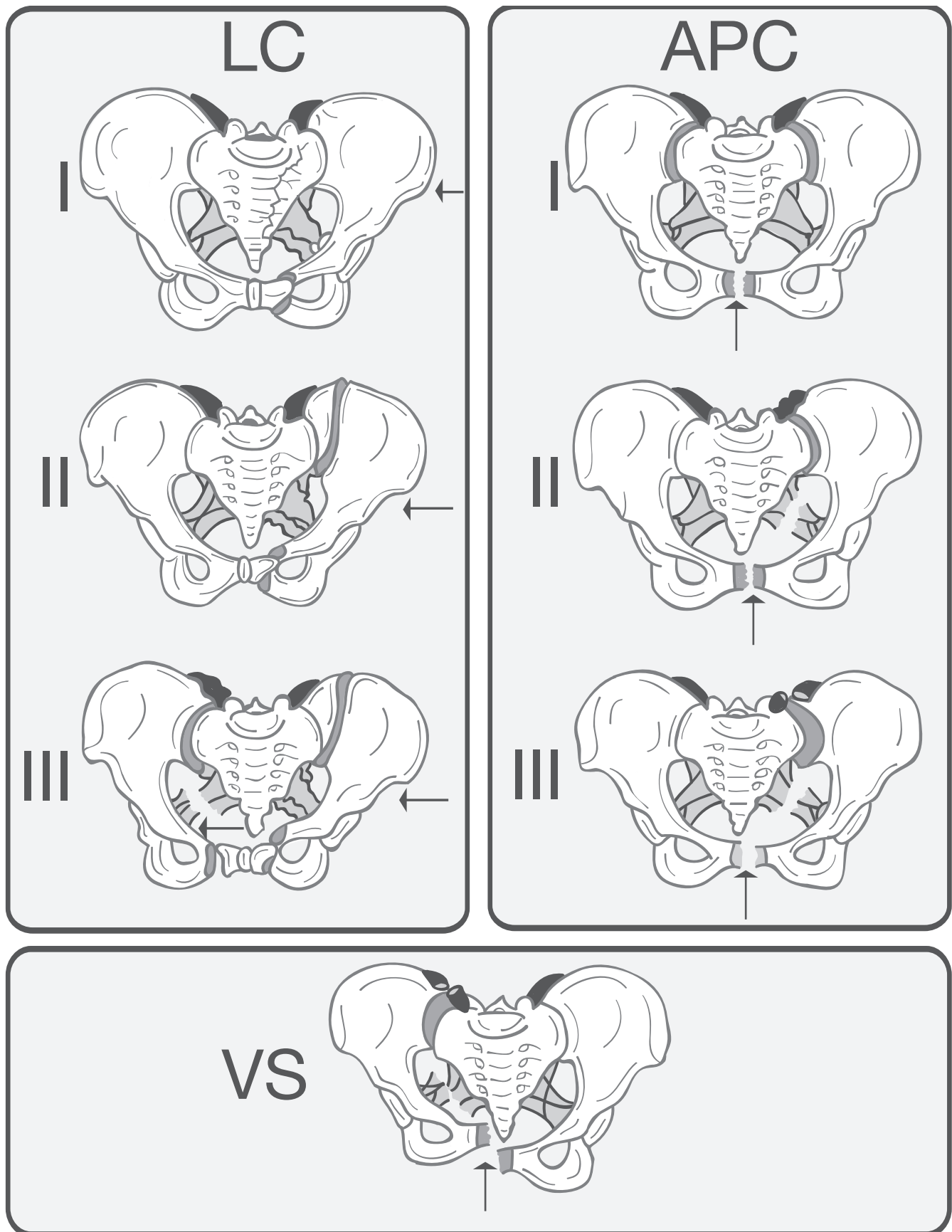
Pelvic fracture classification and correlation with haemorrhage

The two pelvic fracture classification systems most frequently used are the Young-Burgess system shown below, which is based on the direction of injuring force and the Tile classification system, which is based on rotational and vertical stability of the pelvis.²⁷ The Young-Burgess system was utilised in six studies, which compared the potential association between pelvic fracture classification based on the initial AP radiograph and pelvic haemorrhage. A significant correlation was reported between higher blood product requirement and the more severe type of pelvic fracture: LC II and III, APC II and III, VS and combined mechanism.^{6;7;17;19;23;28}

Using the Tile system¹⁶ and a new classification system developed by the authors, based on different locations of pelvic ring fractures,¹⁴ these two studies reported no significant correlation between fracture pattern and blood requirement. A reason for these different findings is the confounding factor of haemorrhage from associated external, intrathoracic or intraperitoneal sources. Up to 50% of pelvic fracture patients may have associated bleeding sources.^{5;6;15;20;24;28-30} Another limitation of the predictive value of classification systems based on the initial AP radiograph to predict haemorrhage is that the initial AP radiograph may not clearly demonstrate major posterior element disruption.^{14;31} In two studies comparing plain pelvic radiographs with CT, 9% and 22% of fractures were not detected on the plain radiographs.^{32;33} Fracture classification systems are also not foolproof in determining whether the bleeding site is anterior or posterior.³⁴

In summary, it is clear that fracture types causing major ligament disruption of the sacro-iliac, sacro-spinous and sacro-tuberous ligaments carry an increased probability of pelvic arterial bleeding.³⁴

Figure 1. The Young-Burgess classification, based on direction of force, showing lateral compression (LC), anterior-posterior compression (APC) and vertical shear (VS) pelvic injuries. Subtypes I, II and III of each classification represent increasing degree of severity.³⁵ The injury classification key is shown below: ²⁷



1.1 Definitions

Haemodynamic instability is defined as a class III or IV hemorrhage leading to a drop in systolic blood pressure below 100 mmHg at the scene and / or initial fluid resuscitation requirement of more than 2000 mL.³⁶

Pelvic fractures are classified according to the Young-Burgess system (Figure 1, P.10) as a disruption of the pelvic ring from a lateral compression (LC) type I, II and III injury, an anterior-posterior compression (APC) type I, II and III injury, a vertical shear (VS) injury or a combination mechanism injury. The more severe types (LC II and III, APC II and III, VS and combined types) often involve disruption of the major pelvic ligaments.²⁷

When following EMST/ATLS principles and facing a circulation problem in combination with a pelvic fracture on the initial pelvic radiograph, clinical practice guidelines are needed on how to determine sources of bleeding, how to control bleeding and which techniques are most rapid and effective. To implement these guidelines, a significant reality component is needed to accommodate for the limits of the institution and availability of personnel.³⁴

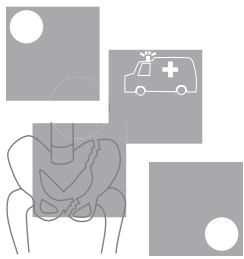
A major challenge for clinicians is the relative infrequent presentation of haemodynamically unstable pelvic trauma patients.³⁷ Furthermore, the potential for associated injuries is a confounding management problem.

Incidence of pelvic fractures at the Major Trauma Service (Liverpool Health Service) and a Rural hospital (Bowral hospital) within South Western Sydney Area Health Service

Between 1999 and 2001, 187 patients presented to Liverpool Health Service with pelvic fractures, representing 1.2% of all fractures seen in this period. The overall mortality rate was 11.2%.

Sixty-seven (36%) of the 187 patients were deemed haemodynamically unstable. Fifteen (22%) of these 67 haemodynamically unstable patients died compared to 6 (5%) deaths out of 120 haemodynamically stable patients. ($p = 0.0003$, chi-squared = 13.05). The odds ratio of death in haemodynamically unstable patients was 5.4 compared with death in haemodynamically stable patients. The primary cause of death in seven of the 15 (46%) haemodynamically unstable patients was caused by pelvic haemorrhage. All 15 haemodynamically unstable patients that died had associated injuries including 7 (46%) head injuries, 5 (33%) chest injuries, 2 (13%) abdominal injuries and 1 (7%) extremity injury.

In the same period, 18 patients presented to Bowral hospital with a fracture of the pelvis. None were haemodynamically unstable and the Injury Severity Score (ISS) varied between 4 and 13. Bowral is the only rural hospital within South Western Sydney Area Health Service.



2 Methods

2.1 Scope of the guidelines

This guideline is intended for use by all clinicians who are involved in the initial care of patients presenting with haemodynamic instability associated with pelvic fractures; ambulance officers, emergency physicians, emergency nurses, surgeons, radiology staff and operating theatre staff.

This guideline has been developed to assist clinicians in providing a more selective, evidence-based approach to the management of these patients.

These guidelines however, are not prescriptive nor are they rigid procedural paths. It is recognised that the guidelines may not suit all patients in all clinical situations. The guidelines rely on individual clinicians to decipher the needs of individuals. They aim to provide information on what decisions can be made, rather than dictate what decisions should be made.

2.2 Aims and objectives of the guideline

Aim

To facilitate the management of haemodynamically unstable pelvic fracture patients, clinical practice guidelines were developed to answer the four key clinical questions shown below.

Key clinical questions

The following points represent the common key situations that arise during the treatment of haemodynamically unstable patients with pelvic fractures:

- 1 How to determine the source of bleeding in haemodynamically unstable pelvic fracture patients?
- 2 How to control pelvic retroperitoneal bleeding with or without intra-abdominal bleeding?
- 3 What is the optimal angiography and embolisation technique?
- 4 What is the optimal way of physically stabilising the pelvis?

2.3 Assessment of the evidence

2.3.1 Level of Evidence

The articles were classified according to their general purpose and study type. From this each article was allocated a Level of Evidence:

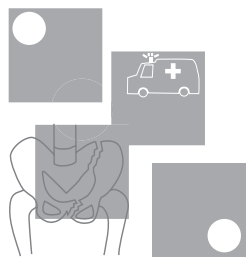
Table 1. Levels of evidence

Level I	Evidence obtained from a systematic review of all relevant randomised control trials
Level II	Evidence obtained from at least one properly-designed randomised control trial.
Level III-1	Evidence obtained from well-designed pseudo-randomised controlled trials (alternate allocation or some other method).
Level III-2	Evidence obtained from comparative studies (including systematic reviews of such studies) with concurrent controls and allocation not randomised, cohort studies, case-control studies, or interrupted time series with a control group.
Level III-3	Evidence obtained from comparative studies with historical control, two or more single arm studies or interrupted time series without a parallel control group.
Level IV	Evidence obtained from a case-series, either post-test or pre-test / post-test

2.4 Consultation processes

A multidisciplinary committee was established consisting of clinicians from Emergency Department, Orthopaedics, Interventional Radiology, and Trauma Specialists.

In the absence of suitable evidence the multidisciplinary working party worked to develop consensus guidelines.



3 How to determine the source of bleeding in haemodynamically unstable pelvic fracture patients?

GUIDELINE	LEVEL OF EVIDENCE
When the haemodynamically unstable patient enters the resuscitation room, a primary survey with full exposure takes place. Carefully inspect for external bleeding sources and examine the long bones. A supine chest x-ray and pelvic X-ray must be obtained within ten minutes of arrival. The CXR will identify a large haemothorax. If the pelvic x-ray shows a pelvic fracture, the remaining two sites of significant bleeding are the abdomen and the pelvic retroperitoneum.	III-3
The probability of associated intraabdominal bleeding with a major pelvic fracture is 32%. The options for assessing intraabdominal bleeding are: Diagnostic Peritoneal Aspiration (DPA) and / or Focused Abdominal Sonography in Trauma (FAST). Both should be completed within 30 minutes of the patient's arrival.	III-3
DPA is a reliable diagnostic test for determining frank blood in the abdominal cavity. The aspiration is positive in the presence of >10 ml of frank blood.	III-3
FAST is a good alternative diagnostic modality for evaluating free fluid in the presence of a pelvic fracture. Most frequently FAST is positive in the right upper quadrant. The suprapubic view is unreliable in pelvic fracture patients. If practical, FAST should be repeated to increase sensitivity.	III-2
When external sources, long bones, intrathoracic injury and intra-abdominal injury do not account for the hypotension in a haemodynamically unstable patient with a major pelvic fracture, pelvic arterial bleeding must be evaluated. The patient should go for immediate angiography.	III-3
In the presence of a pelvic fracture and haemodynamic instability, pelvic arterial bleeding must be evaluated even if other sources of haemorrhage have been identified.	IV
In the rural or urban environment where DPA or FAST is not available, identification of the source of bleeding is reliant on the method of exclusion. Upon exclusion of the other four sources of bleeding and in light of continuing haemodynamic instability it must be assumed that the patient has intraabdominal bleeding until proven otherwise.	Consensus

Probabilities

In a haemodynamically unstable trauma patient with a pelvic fracture there are five potential sites of major blood loss:

- 1 Externally
- 2 Long bones
- 3 Chest
- 4 Abdomen
- 5 Retroperitoneum³⁸

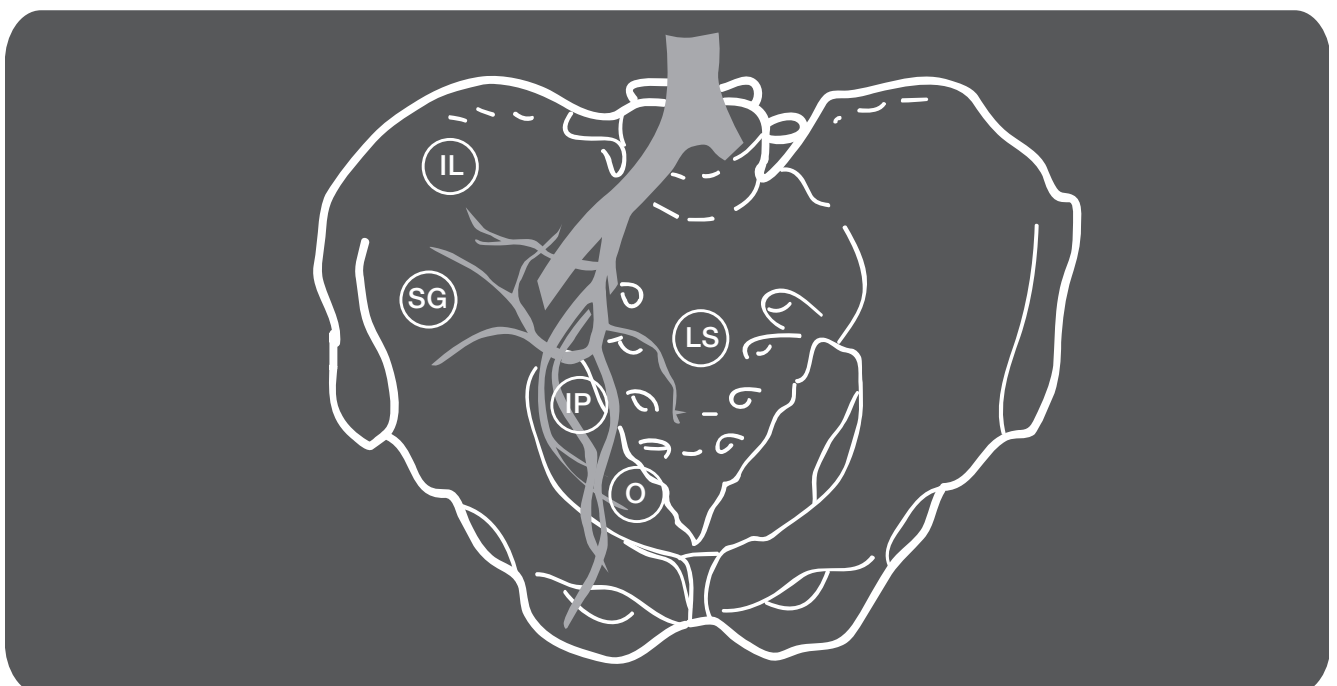
Determining the site of bleeding is paramount. External blood loss requires careful visual inspection. Bleeding from long bone fractures is present in approximately 40% of unstable trauma patients and is usually evident from swelling due to haematoma formation. This is usually a contribution, not a major ongoing cause of blood loss.^{12;28;30}

Intrathoracic haemorrhage is to be expected in 4-29% of cases^{15;28-30} and can be evaluated on a chest X-ray, which should be performed within 10 minutes of the patients arrival.³⁹ There are minor limitations to first mobile supine chest X-ray. A small haemothorax can be initially missed in 5% of surviving patients and in up to 18% in non-surviving patients.⁴⁰ However, a large haemothorax contributing to haemodynamic instability should not be missed.

The next part of the decision tree is crucial, trying to decide whether the blood loss is in the abdomen or in the pelvic retroperitoneum or in both. At this point the AP pelvic radiograph should be reviewed. If a pelvic fracture with possible disruption of the pelvic ligaments causing an unstable fracture pattern (APC type II and III, LC type II and III, VS or a combination type injury) is seen or suspected, the probability of pelvic arterial bleeding is 52%.^{6;17;19;20;41-43} In the first prospective study on the safety and efficacy of pelvic angiography Velmahos et al have identified three independent risk factors of pelvic arterial bleeding: age >55 years (Odds Ratio: 8.1), absence of long bone fractures (OR: 3.2) and need for emergent angiography (OR: 2.9). If all three risk factors were present, the probability of pelvic arterial bleeding was 94%, if all three were absent the probability was 18%.⁴⁴

Reported bleeding sites are anteriorly the internal pudendal (27%) and the obturator (16%) arteries. Posteriorly the superior gluteal (25%) and the lateral sacral (23%) arteries are most frequently involved. Other sources include the iliolumbar artery and the inferior gluteal artery (9%). Therefore 43% of arterial bleeding sources are anterior and 57% are posterior.³¹ Varying degrees of venous and cancellous bone bleeding within the retroperitoneum are present in all haemodynamically unstable pelvic fracture patients.

Figure 2. The proximity of the arteries in relation to the pelvis: IL, iliolumbar artery; SG, superior gluteal artery; LS, lateral sacral artery; IP, internal pudendal artery; O, obturator artery



The overall probability of a pelvic fracture with haemodynamic instability associated with intraperitoneal bleeding source is 32%.^{2;6;12;15;19;20;28;30} Seventy-eight per cent of intraperitoneal injuries result in haemorrhage including; the spleen (22%), the liver (20%), the bladder (15%), the bowel mesentery (10%) and diaphragmatic lesions (4%). Renal haemorrhage is found in 7% of cases.^{5;12;19;28;30;45} The remaining 22% of intraperitoneal injuries are not associated with bleeding.

Investigations

Diagnostic Peritoneal Aspiration (DPA) and Focused Abdominal Sonography in Trauma (FAST) are the preferred diagnostic means to determine if there is intra-abdominal bleeding.^{5;14;15;43}

DPA takes less time than Diagnostic Peritoneal Lavage (DPL); only aspiration of intra-peritoneal blood is determined. More than 10 cc of gross blood is considered positive. When performing DPA in patients with a suspected pelvic haematoma, an open umbilical^{46;47} or supra-umbilical technique,⁵ if there is a large retroperitoneal haematoma, with a large bore catheter (20F) is advised.⁴⁶ In the absence of >10 cc of gross blood on direct aspiration through a 20 French catheter, it must be assumed there is no major intra-abdominal bleeding going on at that time. If DPA is negative, Diagnostic Peritoneal Lavage (DPL) effluent should be sent for routine analysis for intestinal perforation, but this has little impact during the phase of haemodynamic instability.

FAST is generally 95% accurate in identifying free fluid in the abdominal cavity.⁴⁸⁻⁵¹ The few studies reporting the utilisation of FAST in pelvic trauma patients report accuracy between 84% and 97%.^{49;52;53} However, in the presence of a pelvic fracture, FAST should be interpreted cautiously as up to 19% false negative rates for free fluid have been reported.⁵⁴ An explanation for this may be that the FAST is performed so soon after the injury that haemorrhage was not yet significant enough to be detected.⁵⁵ Repeating the FAST is a good option as it decreases false negative results and increases sensitivity to around 95%.^{55;56} Therefore, if FAST is not able to be repeated, those with pelvic ring fractures and those that remain haemodynamically unstable in the presence of an initial negative FAST result require continued assessment of clinical condition to exclude intra-abdominal bleeding.⁵¹

In general, regardless of type of injury, intraperitoneal fluid is found most frequently in Morrison's pouch – the right upper quadrant.^{48;51} If a pelvic fracture with retroperitoneal haematoma is present, the haematoma may compress the bladder that is needed as an acoustic window for the detection of free fluid. Therefore the suprapubic FAST view can be difficult to interpret.

Assessment and decision-making

In the presence of a positive DPA and/or free fluid in the abdomen using FAST, in the face of continuing haemodynamic instability immediate laparotomy is warranted.^{5;16;17;34;57}

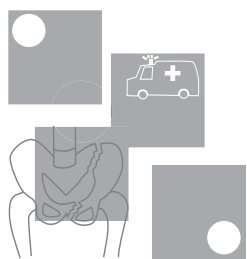
If absence of intra-abdominal bleeding has been determined using FAST and/or DPA, the pelvic retroperitoneum is the last possible source of bleeding. Angiography is recommended as the best next step for locating a retroperitoneal source.^{5;11;13;14;16;17;44;58-62} The haemodynamically unstable patient should not go to CT scanning. If there is a fracture pattern suggestive of a major pelvic ligament disruption, ie LC type III, APC types II and III, VS or a combination type fracture, the probability of a pelvic arterial bleeding source is increased.^{6;17;19;20;23}

The initial AP pelvic radiograph is the only guide to determine the probability of pelvic bleeding. Disruptions involving only the pubic rami do not vertically or rotationally unfasten the pelvic ring, but when recognising a fracture of the pubic bone, posterior disruption and probability of arterial bleeding must always be suspected.^{14;31} One must also bear in mind that bilateral inferior/superior pubic ramus fractures (butterfly type fracture from AP compression mechanism), acetabular fractures and even simple ramus fractures in the elderly can lead to arterial bleeding causing hypotension.^{41;44}

The abdomen may be the most difficult to assess in the rural and urban environment if DPA or FAST is not available. Determining the source of bleeding is then reliant on method of exclusion. The clinician should examine the other 4 sources for blood loss, upon exclusion of these and in light of continuing haemodynamic instability it must be assumed that the patient has intraabdominal bleeding until proven otherwise.

Timeframes

For every three minutes of haemodynamic instability elapsed without haemorrhage control in the Emergency Department, there is a 1% increase in mortality.⁶³ Therefore decision making within pre-determined timeframes is crucial. The haemodynamically unstable pelvic fracture patient should leave the resuscitation room within 45 minutes heading for either angiography or laparotomy. Assessment of external bleeding sources and long bone fractures should take place within the first 5 minutes. The chest X-ray and pelvic X-ray should be performed within 10 minutes of the patients arrival. Assessment of the abdomen with DPA and/or FAST should be completed within 30 minutes.



4 How to control pelvic bleeding with or without associated intraabdominal bleeding?

GUIDELINE	LEVEL OF EVIDENCE
If intra-abdominal bleeding has been excluded by DPA and / or FAST, immediate angiography and embolisation is warranted. Transfer to the angiography suite should take place within 45 minutes of the patient's arrival. Close monitoring, ongoing resuscitation and re-assessment of an intra-abdominal bleeding source utilising FAST and / or clinical parameters are mandatory in the angiography suite.	III-3
Haemodynamically unstable patients with pelvic fractures should be managed with early non-invasive external stabilisation to aid in controlling small venous and cancellous bone bleeding. In the case of a vertical shear type pelvic fracture, supplementary femoral pin traction is necessary on the affected side. External stabilisation does not control arterial bleeding.	III-1
If laparotomy is warranted, a non-invasive or invasive external stabilisation device should be placed concomitantly with laparotomy in the operating theatre. If angiography is warranted, a non-invasive external stabilisation device should be placed prior to transfer in the resuscitation room.	IV
If intra-abdominal bleeding has been determined by DPA and / or FAST, immediate laparotomy is warranted. Concomitant intestinal perforation should be dealt with in a damage control fashion if necessary.	III-3
If at laparotomy, performed for intraabdominal haemorrhage, there is a freely bleeding ruptured pelvic haematoma, packing and immediate transfer to angiography is preferable. Where angiography is not available or the patient is too unstable (blood pressure unable to be restored above 70 mmHg), the haematoma should be evacuated, the internal iliac arteries bilaterally ligated and the pelvis packed.	IV
In the situation of exsanguination at presentation, with little or no response to fluid resuscitation, immediate operation is the only life saving option: Laparotomy with surgical ligation of bleeding arteries, pelvic packing with large sponges and stabilisation of the pelvis.	IV
Internal fixation of major pelvic fractures is contra-indicated in haemodynamically unstable patients.	IV
In the situation where angiography services are not available, management is determined by the degree of haemodynamic instability. In the presence of reasonable haemodynamic stability (SBP>80mmHg), the pelvis should be non-invasively externally stabilised and Retrieval Services should be contacted as a matter of urgency. If the systolic blood pressure drops below 80-90mmHg, small aliquots of fluid (100-200mls) may administered. If the blood pressure becomes increasingly unstable (SBP<80mmHg) and cannot be maintained with small boluses of fluid, immediate laparotomy with surgical ligation of bleeding arteries, pelvic packing with large sponges and invasive external stabilisation of the pelvis is the only life saving option available. An unstable patient should not be transferred where surgical services are available until surgical haemostasis has been achieved.	Consensus

Summary

Numerous techniques to control pelvic haemorrhage bleeding have been described: angiography and embolisation, external invasive fixation of the pelvis, laparotomy with ligation of the internal iliac arteries and pelvic packing with large sponges, internal fixation of the pelvis and non-invasive external stabilisation.

When the abdomen has been cleared as a bleeding source, haemodynamically unstable patients with pelvic fractures should undergo immediate angiography and embolisation to control arterial pelvic bleeding and immediate external stabilisation to control small venous and cancellous bone bleeding.

Laparotomy and external stabilisation have priority over angiography if there is an intraabdominal bleeding source. The only two indications remaining for open surgical arterial ligation and pelvic packing are:

- 1 Ruptured pelvic haematoma at laparotomy when transfer to angiography is not possible or angiography facilities are not available
- 2 The exsanguinating patient unresponsive to resuscitation.

Internal fixation in the haemodynamically unstable patient is contra-indicated.

Pelvic haemorrhage without intraabdominal bleeding

Angiography and embolisation

Once an intraabdominal bleeding source has been excluded or treated, angiography is both diagnostic and therapeutic for pelvic haemorrhage.^{11;13;41;60;64} Margolies was one of the first to report the use of angiography and embolisation as an effective means of controlling pelvic haemorrhage in 1972.⁵⁸

In management strategies in the late seventies and eighties, angiography was indicated for those patients who, after initial fluid resuscitation and orthopaedic pelvic fixation, still had ongoing bleeding from a suspected retroperitoneal source.^{12;14;31;45;65;66}

Angiography was used selectively or as a last resort and reported pelvic arterial bleeding rates were less than 15%.^{15;59;67;68}

In more recent and prospective series, when angiography is used liberally and early in the treatment algorithm, pelvic arterial bleeding rates of 57-64% have been reported.^{19;41;42;44} Embolisation success rates for these patients approach 90%.^{13;41;44} This success of early interventional angiography has shifted the indications for its use and it is now recommended at an early stage in the management of the haemodynamically unstable patient after other sources of haemorrhage have been ruled out.^{5;6;11;16;17;20;44;67;69}

The various forms of arterial injury include transection, laceration, intimal tears, thrombosis, vasospasm, false aneurysm, arteriovenous fistulae and vessel tortuosity. Arteries may be injured by blunt force, stretching force and sharp force from bony edges or tense fascia, such as the piriformis muscle fascia. Transection, laceration, vasospasm, arteriovenous fistulae, false aneurysms and vessel tortuosity are important to recognise and treat in the haemodynamically unstable patient.^{31;58} Injury to the obturator and internal pudendal arteries are frequently seen in association with fractures of the pubic rami.^{31;58} The superior gluteal artery (25%) and the lateral sacral artery (23%) may be traumatized with disruption/fractures near the sacro-iliac joint.³¹

Arterial embolisation is effective by stopping the arterial bleeding and allowing the tamponade effect of the haematoma to control venous and cancellous bone bleeding.

Complications of embolisation have been reported in limited case series and include necrosis of the distal colon and ureter, bladder necrosis and perineal wound sepsis.⁶⁰ In larger and prospective patient series, even using bilateral internal iliac artery embolisation, the use of unselective and selective embolisation has been reported to be safe, with minimal morbidity.^{13;41;42;44}

Physicians should abandon the reluctant attitude to transport haemodynamically unstable patients to the angiography suite. Left in the Emergency Department or Intensive Care unit, these patients may die from exsanguination.³⁴ Rather, the angiography suite should be prepared as a mini-ICU with close monitoring, ongoing resuscitation and re-assessment of other bleeding sources by dedicated clinicians.⁴⁴ FAST should be repeated at least once during angiography to monitor an intraabdominal bleeding source.

Pelvic stabilisation

Osseous stabilisation of the pelvis has a role in the management of haemodynamically unstable pelvic fractures. In rotationally unstable, but vertically stable fractures (LC type III, APC types II and III), a form of external stabilisation is recommended, achieving 64-83% stabilisation rates. Biomechanically, rotational stabilisation is not effective if the hemipelvis is also vertically displaced on the initial AP pelvic X-ray (VS type, combination type), achieving only 27% stabilisation rates without supplementary skeletal traction or subsequent internal fixation.^{70;71}

In promoting control of haemorrhage in patients with major pelvic fractures, the role of external stabilisation has not been fully elucidated. Many authors have advocated early invasive external fixation devices.^{8;14;19;25;34;59;70;72} However, there is only one prospective trial with randomisation promoting immediate invasive external fixation. In the group allocated to immediate invasive external fixation, blood transfusion, post-operative pain and late deformities were significantly less.⁷³

One theory is that reducing the pelvis back to its normal configuration with external fixation reduces pelvic volume, and therefore limits the amount of blood loss to the retroperitoneal pelvic haematoma.⁷⁴ This theory supported smaller pelvic volume promoting tamponade of pelvic bleeding sources.⁶⁶ However, other studies showed there was little effect of external fixation on the diameter of the pelvic ring and the pressure-volume characteristics of the pelvic retroperitoneum. In all pelvic fractures with haemodynamic instability there is a variable amount of retroperitoneal pelvic bleeding from the exposed cancellous bone surfaces and the disrupted pelvic venous plexus.

Current opinion favours a concept that re-apposing these bony pelvic surfaces back into reasonable alignment allows the haemostatic pathways to control venous bleeding from small veins and exposed cancellous bone.⁷⁵⁻⁷⁷ Low-pressure venous bleeding may be tamponaded by external stabilisation given that enough fluid volume (clot) is present in the pelvic retroperitoneum.⁷⁶ Maintaining them in stable, non-moving apposition could also prevent repeated trauma to already clotted vessels, thereby also lessening consumption of clotting factors.⁷⁶ It seems likely that aspects of these theories are correct and supports the rationale behind early external stabilisation to achieve a better degree of venous haemorrhage control and bony alignment.⁷⁵

Another advantage of early external stabilisation is that it relieves pain from shearing bony surfaces and allows patients to sit up in the Intensive Care Unit. This contributes to preventing ventilatory adverse effects and allows better nursing care.^{69;71} In addition, better mobility, less leg-shortening and less obstetric complications in the longer term are described after early external fixation.^{69;71;72}

If an intra-abdominal bleeding source has been excluded and angiography is warranted, non-invasive external stabilisation (see Section 6 – How to optimally mechanically stabilise the pelvis, p.25) should be applied in the emergency department. If laparotomy for intra-abdominal bleeding is warranted, immediate transfer to the operating theatre takes place and non-invasive or invasive radiolucent external stabilisation (see Section 6 – How to optimally mechanically stabilise the pelvis, p.25) should be applied concomitantly with laparotomy. Through a tension band effect on the iliac wings, the anterior abdominal wall contributes to limiting the degree of anterior pubic diastasis, which will increase if the pelvis is not stabilised prior to the midline incision.^{70;74;75;77;78} This theory supports external stabilisation of the pelvis before or concomitantly with laparotomy.⁷⁵

Laparotomy to control pelvic haemorrhage

With the availability of therapeutic angiography, laparotomy to control pelvic retroperitoneal haemorrhage in pelvic fracture patients is no longer indicated. Laparotomy and pelvic retroperitoneal exploration may not only fail to arrest haemorrhage but may also put the patient at risk. By opening the abdomen, the surgeon can directly contribute to aggravation of pelvic haemorrhage due to decompression of the tamponade effect of the abdominal wall.^{44;57;58;62} In this scenario laparotomy may be non-therapeutic.

In most circumstances, venous pelvic haemorrhage is contained within the pelvis by the pelvic bones, the fibromuscular pelvic floor and the parietal peritoneum superiorly. If the parietal peritoneum is breached by the expanding retroperitoneal haematoma or iatrogenically during laparotomy, exsanguination may occur. Before therapeutic angiography there was frustration reported with the inadequacies of direct operative exposure and ligation of the internal iliac artery or branches of it deep in the pelvis.^{2;57;68;79} This is primarily because anastomotic pathways remain between the peripheral internal iliac branches and the inferior mesenteric artery, inferior epigastric arteries, circumflex and perforating branches of the deep femoral arteries and lumbar arteries.^{20;64}

Pelvic haemorrhage with intraabdominal haemorrhage

Laparotomy for intra-abdominal haemorrhage

A positive DPA and/or FAST in the haemodynamically unstable patient with a pelvic fracture warrants immediate laparotomy.^{5,75} Concomitant small bowel or colon injury should be dealt with in a damage control fashion if the patient's physiology necessitates this.

During laparotomy, in the situation where a ruptured pelvic haematoma is freely bleeding into the abdomen, there are two possible scenarios. If the patient's physiologic status is poor, blood pressure is unable to be supported above 70 mmHg and/or interventional radiology is not available within one hour, surgical ligation of arterial bleeding and packing of the pelvis remains the only life-saving option.¹⁸ If physiologic status and blood pressure is stable and interventional radiology is available within one hour, the haematoma can be packed and the abdomen closed in a temporary fashion, followed by immediate angiography and either non-selective bilateral embolisation of the internal iliac arteries⁴⁴ or selective embolisation.

In the situation of controlled intra-abdominal haemorrhage and a contained moderate to large pelvic haematoma is seen during laparotomy, the pelvis should be packed with large sponges to add to tamponade and the abdomen closed in a temporary fashion, followed by immediate angiography and embolisation.⁴⁴

The exsanguinating patient

In the desperate setting of an exsanguinating patient in the resuscitation room with little or no response to resuscitative measures and blood pressure unable to be restored to above 70 mmHg, immediate operation is the only life-saving option. If the patient can be brought to the operating room and assuming associated external and thoracic injuries are controlled, the last option at laparotomy to control pelvic arterial bleeding in the face of exsanguination is bilateral internal iliac artery ligation. To control small arterial and venous bleeding, packing the pelvis with

large abdominal sponges is effective.^{18;69} In Ertel's series of twenty consecutive patients, five patients underwent emergency room laparotomy with pelvic packing and nine patients underwent immediate operating room laparotomy and pelvic packing. In three patients an additional thoracotomy was performed due to lack of vital signs, of which only one patient survived. In two patients the aorta was cross-clamped and both of these patients died.¹⁸ A posterior external fixation C-clamp was applied in all patients. Utilising this approach 64% of patients undergoing emergency operating procedures survived and 36% developed an abdominal compartment syndrome, which was successfully relieved by decompressive laparotomy. One case of ischaemic ileum and subsequent multi-organ failure was seen.¹⁸

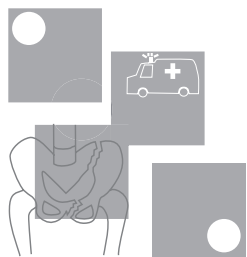
Other techniques

Internal Fixation

Internal Fixation provides a better biomechanical stabilisation of the pelvis, but is contra-indicated in the haemodynamically unstable patient, as it is time-consuming and exposing the fracture surfaces can cause decompression of the pelvic haematoma and uncontrollable haemorrhage.^{71;80}

The Military Anti-Shock Trousers (MAST)

Historically, the Military Anti-Shock Trousers (MAST) has been advocated as an external splinting device for pelvic fractures and promoting tamponade of small vessel bleeding.^{5;6;15;69} In the late 1980's there was increasing evidence that early external fixation was as good as or better than the MAST for haemorrhage control.^{5;14} The MAST has also been criticized for its limiting access to the abdomen, groin and perineum. Other described risks are untreatable hypovolaemia at removal and compartment syndrome when applied for too long.^{28;71} In a prospective study, the complications associated with the MAST, causing compression of the lower extremities and abdomen outweighed its benefits.⁸¹ For these reasons the use of the MAST has been limited. If any, its role lies in the pre-hospital setting when ambulance personnel may use it as a valuable temporising manoeuvre during transport, especially in areas with longer transportation times or in rural to urban transfers.^{6;14;28;69;71}



5 What is the optimal angiography and embolisation technique?

GUIDELINE	LEVEL OF EVIDENCE
If a major pelvic fracture is seen on the initial pelvic x-ray in the haemodynamically unstable patient, the interventional radiologist and nursing staff should be notified immediately. It is critically important that the general surgeon coordinates care between emergency clinicians, interventional radiologist, orthopaedic surgeon, intensive care specialist, nursing and blood bank.	IV
Angiography should be performed as soon as the abdomen has been cleared as a source of bleeding or within 90 minutes of presentation. A femoral approach is preferred, but a left brachial puncture may be needed in patients in which femoral approach fails.	IV
Using 4 or 5 Fr catheters, angiography begins with a midstream abdominal flush to reassess any abdominal bleeding. A pelvis flush is then performed at aortic bifurcation level. An arterial haemorrhage requiring embolisation should present itself at the pelvis midstream flush.	III-3
Any sites of contrast extravasation, false aneurysms and occlusion of the mainstem internal iliac artery warrant embolisation. Vasospasm due to major haemorrhage may obscure bleeding distal to the spasm.	IV
Non-selective embolisation of main arteries, such as the internal iliac arteries or their first divisional branches should be performed with steel coils. Steel coils are also preferred for selective embolisation of bleeding branches. In patients with multiple distal, small branch bleeding sites a shower of gelfoam slurry can be utilised.	IV
Selective embolisation of smaller branches should be used judiciously. If respiratory or hemodynamic instability increases during angiography, non-selective bilateral embolisation of the internal iliac arteries with steel coils should be performed. Complete occlusion of the internal iliac artery is an acceptable alternative to exsanguination.	IV
Once a vessel is embolised for distal branch extravasation, the potential collateral vessels of both internal iliac arteries should be evaluated to identify additional supply to the injured vascular bed. Completion angiography is necessary to document cessation of bleeding.	IV

Considerations and timing

Early anticipation of the need for embolisation and alerting the interventional radiologist and nursing staff in advance is essential. Coordination between Emergency department, general surgeon, interventional radiologist, orthopaedic surgeon, intensive care specialist, nursing and blood bank are critical in the management of haemodynamically unstable patients going to the angiography suite.⁴¹

When anticipating angiography, a non-invasive pelvic stabilising device (sheet, proprietary device) should not obscure access to the femoral arteries. If applying an invasive external fixation device before angiography, the orthopaedic surgeon should use carbonated (radiolucent) connecting rods to facilitate angiography or subsequent CT.

Agolini reported a mortality of 17% if embolisation was performed within three hours of presentation. This increased to 75% mortality after three hours. Patients who had delayed arrival to the angiography suite because of prolonged resuscitation, non-therapeutic laparotomy or unnecessary diagnostic tests had a higher mortality rate.⁴¹ Just as laparotomy controls intraabdominal haemorrhage, angiography with embolisation controls arterial pelvic haemorrhage. Angiography should therefore be performed as soon as possible. The preferred timeframe is within 90 minutes of arrival or as soon after the abdomen has been cleared as a source of haemorrhage.

Catheter insertion

A femoral puncture approach is preferred with the Seldinger technique. Arterial duplex or fluoroscopically guided puncture may be needed if massive haematoma prevents palpation of the femoral pulse. Fluoroscopic guidance utilises the middle third of the acetabular roof as a landmark for the Seldinger needle.¹³ Bilateral punctures may be required. A sheath with a reflux preventing seal is recommended to protect access during catheter exchanges.⁸²

A left brachial approach with a Headhunter-1 catheter⁵⁰ is an alternative in patients when the femoral approach fails. The 100-110-cm-long Headhunter (selective cerebral) catheter is long enough to reach the internal iliac artery and because it's gently curved tip is designed to enter the carotids through brachial approach, it is also effective when cannulating the internal iliac artery from above.⁸²

Acquisitions and findings

The procedure begins with an abdominal flush to re-assess any abdominal bleeding focus. A pelvic flush is then performed using 4 or 5 fr catheters at aortic bifurcation levels (40ml contrast at 15ml/s) with extended filming. As a general rule an arterial haemorrhage requiring embolisation should present itself at the midstream flush. However, selective internal and external iliac artery runs using appropriate oblique projections are recommended and extravasation of contrast on these views also warrant embolisation. A 4 or 5 Fr Cobra or Simmons 1 or 2 catheters are used for these selective runs.⁸² The lumbar arteries should be surveyed, as these can be injured in pelvic fracture patients.^{13;82}

In descending order of frequency, the internal iliac branches that are most commonly injured are the:

- internal pudendal (27%)
- superior gluteal (25%)
- lateral sacral (23%)
- obturator (15%)
- inferior gluteal (6%)
- ilio-lumbar (3%) arteries.^{31;83}

The manifestations of arterial injury may consist of any arterial abnormality:

- Extravasation is the clearest and most obvious finding in transected or lacerated arteries or in arteriovenous fistulae. The typical, increasingly dense extravascular collection of contrast material may be transitory if it dissipates into a large hematoma. Transient areas of increased opacity seen at nonselective imaging require further evaluation.
- Extravasation from injured smaller vessels (1-2 mm in diameter) is often self-limited in normothermic patients with normal coagulation parameters; in trauma patients with hypothermia and coagulopathy, this may not occur. A corollary is that the angiographic abnormality is not always proportional to the actual amount of blood loss from the injury.
- False aneurysms, or well-circumscribed collections of contrast material that extend beyond the confines of the arterial wall, may appear stable. However, after an acute injury, these collections are not confined by chronic fibrotic tissue and are best characterized as pulsatile hematomas that require treatment.

- Occlusions and vessel tortuosity may be stable injuries, but bleeding may be intermittent and may depend on the changing parameters of coagulation, blood pressure, and motion of fracture fragments. Larger branch occlusions warrant embolisation.^{83;84}
- Vasospasm is a frequent finding in haemodynamically unstable patients. Profuse vasoconstriction from major haemorrhage may obscure bleeding sites distal to the spasm.⁴⁴

Embolisation and materials

Main arteries, such as the internal iliac arteries or their first divisional branches should be embolised by steel coils. Steel coils are preferred over gelfoam pledgets in these large-bore arteries. Selective embolisation of bleeding branches is preferred by placing steel coils proximal to the extravasation site. In patients with multiple distal, small branch bleeding sites, scatter embolisation with a gelfoam suspension (small gelfoam particles mixed with contrast material) is utilised. The bleeding sites are showered with these multiple gelfoam particles and provide temporary occlusion without significant ischaemia until the gelfoam dissolves.⁸² Fine particles, utilised in cancer therapy, should not be introduced because of risk of pelvic ischaemia.^{13;41;60}

Selective embolisation should be used judiciously in patients who are unstable. If ventilation becomes difficult or hemodynamic instability increases during the procedure, rapid non-selective embolisation of an entire anterior or posterior division or even bilateral embolisation of the internal iliac arteries (97% success rate) is preferable to an elegant but long

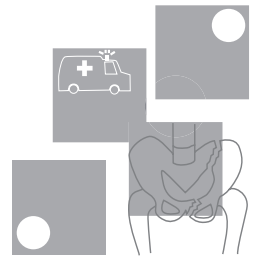
selective embolisation. Complete occlusion of the internal iliac artery is an acceptable alternative to exsanguination.⁴⁴ After this temporising intervention, leaving the groin sheath in case of repeat angiography, the patient can be transferred for operative management if necessary or to the intensive care unit.

Afterward, planned repeat angiography can be performed for selective embolisation of lumbar, lateral sacral, iliolumbar, or replaced obturator arteries that may require additional time for selective catheterisation.

Haemorrhage is identified and treated, after which the diagnostic evaluation is resumed. Once a vessel is embolised for distal branch extravasation, the local potential collateral vessels are evaluated to identify additional supply to the injured vascular bed. Multiple communicating channels between the two internal iliac arteries exist. In particular, evaluation of the ipsilateral and contralateral potential collateral supply follows embolisation of internal iliac anterior division visceral branches or lateral sacral branches.⁸²⁻⁸⁴ Similarly, after treatment of extravasation in pubic ring fractures, the common femoral artery is evaluated for injury to a replaced obturator or external pudendal artery.

Completion angiography is necessary to document cessation of bleeding and to screen for previously unsuspected sites of extravasation or collateral supply.^{83;84} The catheter sheath can be left in, so angiography can be repeated if necessary.

6 How to optimally mechanically stabilise the pelvis?

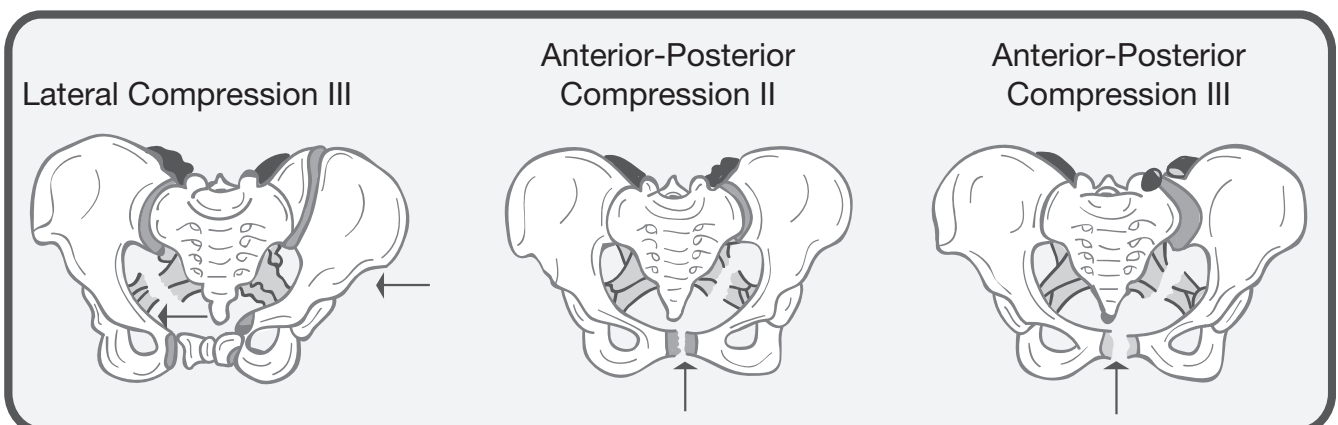


GUIDELINE	LEVEL OF EVIDENCE
Rotationally unstable APC types II and III, LC type III pelvic fractures benefit most from external stabilisation. If vertical instability is also present, such as in VS and combination type pelvic fractures, rotational stabilisation needs to be supplemented by skeletal traction on the injured side.	III-3
The optimal time-effective and safe pelvic external stabilisation device in the haemodynamically unstable patient is non-invasive. A bed sheet wrapped and clamped tightly around the pelvis is a good option. There are a variety of non-invasive proprietary devices available. The device should be applied so that it allows both laparotomy access and femoral artery access for angiography.	IV
Invasive anterior external fixation devices for rotational stabilisation should only be applied when non-invasive devices fail, interfere with procedures or if more time is needed until definitive internal fixation.	IV
The simplest effective form of invasive anterior external fixation consists of a single 5-mm Schantz pin on each side, connected to two radiolucent bridging bars in a triangular construct or a single radiolucent curved rod. The apex of the triangle or top of the curve of should be placed inferiorly in the midline of the pelvis, allowing laparotomy access and the patient to sit up.	III-3

Types of pelvic fractures that benefit from stabilisation

The best results of pelvic stabilisation are achieved in rotationally unstable pelvic fractures: LC type III and APC types II and III. In these types, stabilisation can be achieved in 64-83% of cases.^{70;71} If vertical instability is also present, such as in vertical shear (VS) type injury or a combination type injury, stabilisation can be achieved in only 27% of cases and additional skeletal traction is needed in the other 73%.^{70;71;85}

Figure 3. Types of pelvic fractures that benefit from stabilisation



Biomechanics

Internal fixation has been proven to give the greatest biomechanical stability, but it is impractical for emergency use.^{71;86} To obtain rotational stability, multiple types of anterior and posterior external fixation devices are in use in bridging the gap to definitive internal fixation. When comparing these different kinds of anterior and posterior invasive external fixation devices, all performed similarly based on their ability to prevent rotational pelvic expansion and application times.⁸⁵⁻⁸⁷

Approach in the emergency setting

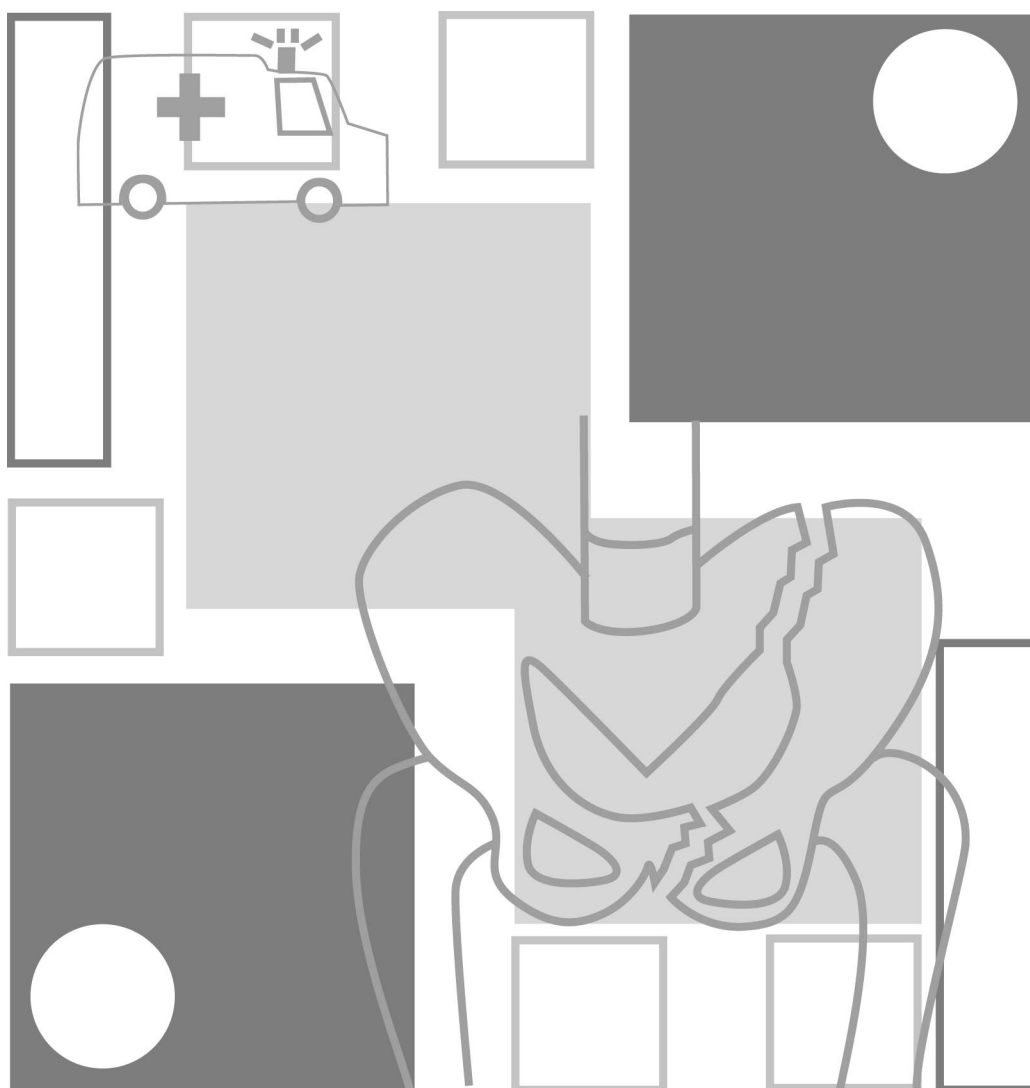
In the situation of haemodynamic instability, stabilisation of the pelvis in APC type II and III, LC type III, VS and combinations of these fractures, must be performed in the shortest possible time. Two kinds of pelvic stabilisation can be considered: non-invasive techniques and invasive fixation.

Non-invasive techniques have advantages: they are safe, time-effective, do not require the presence of an orthopaedic surgeon in the resuscitation room and do not interfere with further resuscitation efforts.⁸⁸ Simple, popular options include the use of a bed sheet wrapped and clamped tightly around the pelvis or a vacuum beanbag to provide emergent pelvic stability. (36;78;88) There are also a number of more expensive proprietary devices specifically designed and marketed for such use. These non-invasive options should be considered as temporising measures bridging the gap from injury to more definitive stabilisation.⁷⁵

Pelvic stability promotes venous bleeding tamponade and protects the soft tissues from further injury.^{70;87} The application of an invasive anterior external fixation frame is recommended in cases of ongoing venous bleeding.^{70;78} These fixators, although effective in preventing pelvic rotational expansion, have problems. Certain fracture patterns do not allow placement of the pins into the iliac crest. Pin site infections compromise subsequent open reduction and internal fixation.^{78;89} Large, bulky frames with multiple pins into the iliac crest are to be considered obsolete in patients, which have been haemodynamically unstable. They prevent proper re-laparotomy access, interfere with angiography and prevent chair mobility by limiting hip flexion.⁷⁸

The pelvic antishock clamp or C-clamp effectively limits expansion of the posterior elements if placed properly.⁹⁰ However, clamp application is unfamiliar to most orthopaedic surgeons to apply, particularly in patients with morbid obesity or severe pelvic deformity. Without fluoroscopy, pins might be placed through the sciatic notch, with the potential for complications. In addition, transforaminal sacral fractures make application dangerous, as over compression can damage nerve roots in these cases.⁷⁸

If an invasive anterior external fixation device is applied, the simplest effective form consists of a single 5-mm Schantz pin on each side either into the iliac crest or the supraacetabular region anteriorly, connected to two carbonated, radiolucent bridging bars in a triangular construct.⁹¹ The apex of the triangle should be placed inferiorly in the midline of the pelvis and over the groin area rather than over the lower abdomen to allow access into the abdomen should laparotomy be necessary.^{70;91} Alternatively a single curved radiolucent rod may be used.



Evidence table

Author & year	Level of evidence	Finding
Agolini 1997 ⁴¹	IV	A review of 35 unstable pelvic fracture patients treated with early angiography. Fifteen required embolisation. Angiographic yield was 64% and success rate of embolisation was 100%. Morbidity and mortality increased if angiography was performed later than three hours after presentation to endotracheal tube in success rate, difficulty of insertion, and time to position correctly in this patient population. The laryngeal mask however does not reliably protect against aspiration and is therefore only recommended when more conventional methods of airway management fail. Further studies in the trauma scenario are indicated.
Ali 2002 ³⁷	III-2	Cognitive and clinical performance was analysed among physicians who treated more than 50 and less than 50 trauma patients per year. Immediate and progressive cognitive skill attrition was worse in the low volume group. Global skills and adherence to ATLS principles were similar in both groups.
Ballard 1999 ⁵⁶	III-2	A prospective protocolled study assessing the accuracy of Focused Abdominal Sonography in Trauma (FAST) in 74 pelvic trauma patients. True negative exams: 71%, true positive exams: 5%. There were no false positive exams, but 17.5% false negative exams. Of the false negative ultrasounds, most occurred in patients with pelvic fractures. Sensitivity was therefore 23.5% with a specificity of 100% and an accuracy of 81.4%.
Bassam 1998 ¹¹	III-2	Results of protocolled management of 15 patients with pelvic fracture after clearing the abdomen of hemorrhage. External fixation was performed for anterior pelvic fractures and angiography was performed for posterior fractures. Bleeding was primarily controlled in all patients undergoing initial angiography, but in only 50% of the patients undergoing initial external fixation. The other 50% required further angiography. Blood transfusion requirements were increased in the external fixation group due to delay in hemorrhage control.
Bode 1993 ⁵⁵	III-2	Retrospective review of 353 nontrivial blunt abdominal trauma patients undergoing abdominal ultrasound. Sensitivity was 92.8% and specificity was 100%. Accuracy was 99.4%; positive predictive value was 100%. Findings at ultrasound were compared with findings at laparotomy, other diagnostic studies and clinically at follow-up.
Broos 1992 ⁷¹	III-3	Prospective review of 35 patients with complex pelvic ring fractures treated with anterior external fixation. 18 patients had rotationally unstable and 17 patients had rotationally and vertically unstable pelvic fractures. Six months to three years post-injury rotationally and vertically (Young Burgess VS type, Tile C type) unstable fractures had significantly more pain, diminished functional capacity and permanent deformity compared to only rotationally unstable fractures. The external fixator provides a good initial splint, but cannot maintain stability in both rotational and vertical unstable fractures.
Cryer 1988 ⁶	III-3	A review of 243 consecutive pelvic fracture patients. Based on the Pennel and Sutherland classification, fracture patterns were correlated with blood transfusion requirement. With 90% confidence 50 to 69% of patients with unstable fractures will require more than 4 units of blood, 30 to 49% will require more than 10 units, 36 to 55% will have intra-abdominal associated injury and 6 to 18% will have pelvic arterial bleeding. In contrast 75 to 85% of patients with stable fracture types will require less than 4 units. Classification of pelvic fractures based on the initial AP radiograph can predict the group of patients at risk for severe hemorrhage.
Dalal 1989 ²³	III-3	Review of 343 patients subdivided into APC, LC, VS and combined mechanism injury. As LC increased from grade 1 to 3 there was increased incidence of pelvic bleeding and retroperitoneal haematoma. As APC increased from 1 to 3 there was increased incidence of injury to spleen, liver, bowel and pelvic bleeding. Grade of APC correlated most with 24-hour volume requirement. Mechanical force type and severity of pelvic fracture were considered keys to the expected organ injury pattern.

Author & year	Level of evidence	Finding
Eastridge 1997 ¹⁰	IV Retrospect	ive review of 111 pedestrians with major pelvic fractures. Mean ISS was 29.2. Associated injuries were 27% neurologic, 26% thoracic, 14% abdominal. There were 71% lateral compression, 21% anterior-posterior compression, 5% vertical shear and 3% combined mechanism type fractures. As severity of pelvic increased according to the Young Burgess classification, Glasgow Coma Scale decreased and fluid resuscitation volume, associated injuries and mortality increased. Severity of injury was correlated with the degree of destructive energy on the body as a whole, as manifested by the number and severity of associated injuries and mortality.
Eastridge 2002 ¹⁹	III-3	Retrospective review of 86 haemodynamically unstable pelvic fracture patients requiring ongoing resuscitation. All underwent laparotomy and/or angiography. In the stable fracture pattern group 85% of 40 patients had intraabdominal haemorrhage contributing to hypotension and 25% died. In the 46 unstable fracture pattern patients (Lateral Compression type II, III, Anterior-Posterior Compression type II, III, Vertical shear or Combined mechanism), 59% had arterial retroperitoneal bleeding and 52% died. Conclusion was that in unstable fracture patterns, even in the presence of haemoperitoneum, consideration should be given to angiography before laparotomy.
Ertel 2001 ¹⁸	IV	Prospective study of 20 consecutive multiply injured patients (mean ISS 41.2 ± 15.3) with haemodynamically unstable pelvic fractures. A posterior C-clamp was placed for primary stabilisation within 57 ± 30 minutes after arrival. With massive haemorrhage 14 patients underwent laparotomy with pelvic packing. Three required additional thoracotomy and aortic clamping. Four died of exsanguination after a mean of 5.4 hours. One died from sepsis after 23 days. Laparotomy with pelvic packing after initial C-clamp application ameliorates mortality in torrential haemorrhage.
Evers 1989 ⁵	III-2	A DPL driven protocol was used in 83 pelvic fracture patients. DPL was highly accurate of intra-abdominal hemorrhage when grossly positive. Microscopic positive DPL did not reflect intra-abdominal hemorrhage contributing to haemodynamic instability. Grossly positive DPL warrants immediate laparotomy. External fixation should be performed during laparotomy. If haemodynamic instability persists or a large pelvic haematoma is identified at laparotomy, angiography should be organized. When the supraumbilical is grossly negative, the pelvis should be stabilised followed by pelvic angiography.
Fleming 1973 ⁷⁹	IV	Case series of 11 patients with pelvic crush injuries from the early 1970s. Five patients were explored in the pelvis control bleeding. Four of the 6 non-explored patients died as compared to two of the five explored patients. The 80% decrease in blood product requirement of the second 48 hours in hospital indicated favorable results of retroperitoneal surgical hemorrhage control.
Broos 1992 ⁷¹	III-3	Prospective review of 35 patients with complex pelvic ring fractures treated with anterior external fixation. Eighteen patients had rotationally unstable and 17 patients had rotationally and vertically unstable pelvic fractures. Six months to three years post-injury rotationally and vertically (Young Burgess VS type, Tile C type) unstable fractures had significantly more pain, diminished functional capacity and permanent deformity compared to only rotationally unstable fractures. The external fixator provides a good initial splint, but cannot maintain stability in both rotational and vertical unstable fractures.
Cryer 1988 ⁶	III-3	A review of 243 consecutive pelvic fracture patients. Based on the Pennel and Sutherland classification, fracture patterns were correlated with blood transfusion requirement. With 90% confidence 50 to 69% of patients with unstable fractures will require more than four units of blood, 30 to 49% will require more than 10 units, 36 to 55% will have intra-abdominal associated injury and 6 to 18% will have pelvic arterial bleeding. In contrast 75 to 85% of patients with stable fracture types will require less than 4 units. Classification of pelvic fractures based on the initial AP radiograph can predict the group of patients at risk for severe hemorrhage.

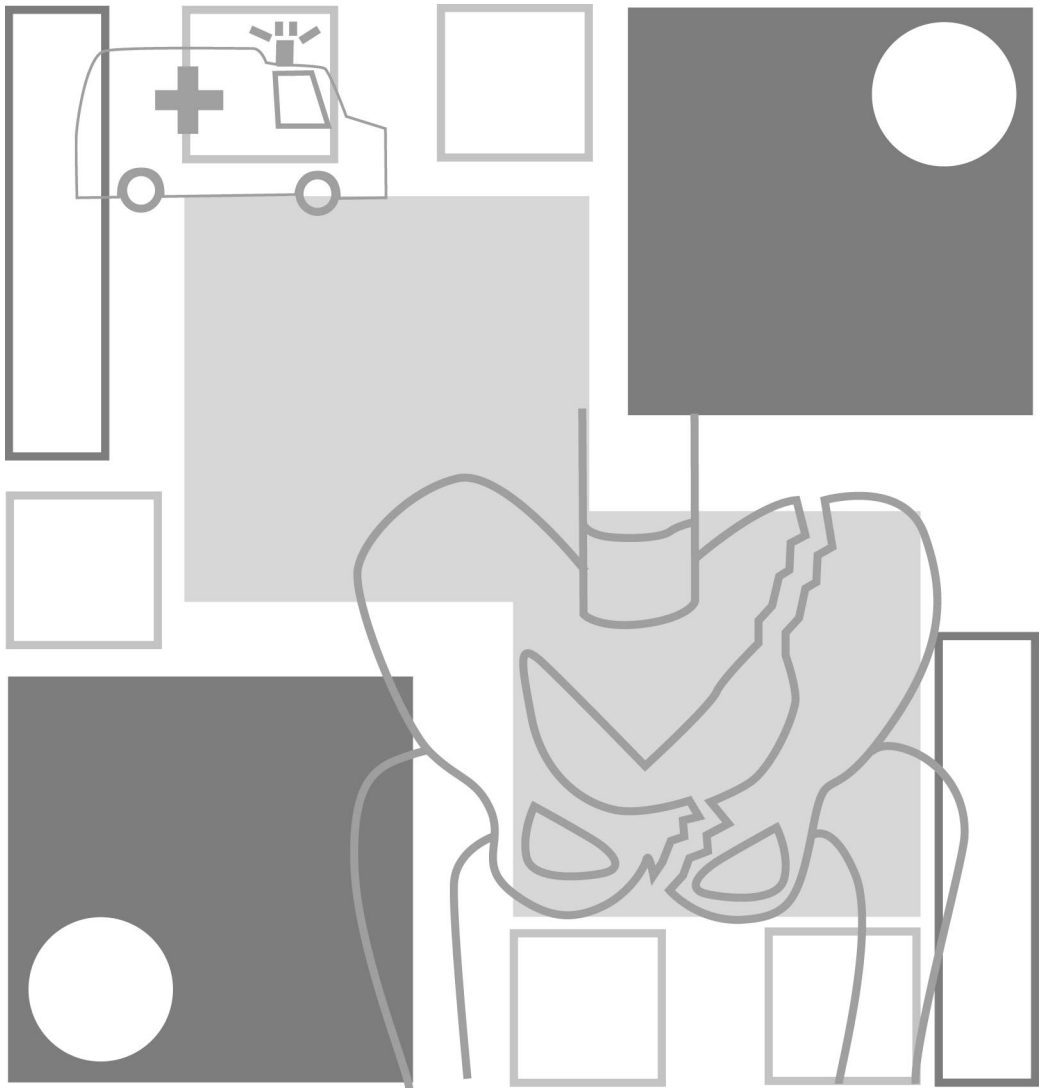
Author & year	Level of evidence	Finding
Flint 1990 ¹⁵	III-3 Review of	Forty-two pelvic fracture patients with criteria for severe bleeding. All were treated according to a protocol including early pelvic stabilisation in the form of anti-shock trousers or external fixation of the pelvis. Embolisation was used in 26% of cases. The study demonstrated that 74% of severe bleeding from pelvic fractures will stop with progressive resuscitation including blood products and pelvic stabilisation.
Garcia 2000 ⁸⁵	III-2	A biomechanical study using the Finite Element Method (FEM), which can measure complex geometries. FEM simulated the mechanical ability of several different anterior external and internal fixing devices to stabilise unstable pelvic fractures. Rotationally instability was effectively stabilised, but with added vertical instability external fixation was not effective. Adequate stability was only achieved by internal fixation.
Ghanayem 1995 ⁸⁷	III-3	Biomechanical study using a cadaveric model comparing three devices for pelvic ring stabilisation: the pelvic C-clamp, the anterior external fixator and the pelvic stabiliser. Pelvic volume was assessed using CT scanning. Based on their ability to reduce pelvic volume and pubic diastasis and their application time all three devices performed similarly.
Ghanayem 1995 ⁷⁷	IV	Unilateral open-book type pelvic ring injuries were created in 5 fresh cadaveric specimens. Pelvic volume was measured for the intact pelvis and disrupted pelvis. Volume was also measured with a laparotomy incision opened and closed. Third, volume was measured in a stabilised disrupted pelvis using an external fixator with the laparotomy incision opened. The average volume increase between a non-stabilised pelvis with the abdomen closed and then opened was 423 cc, a 15% difference. The average volume increase between a stabilised and non-stabilised pelvis, both with the abdomen open, was 692 cc, a 26% difference. Pubic diastasis increased from 3.9 to 9.3 cm in a non-stabilised pelvis with the abdomen closed and then subsequently opened. An intact abdominal wall contributes to stability of the pelvis, therefore stabilisation prior to laparotomy incision is advocated.
Gilliland 1982 ⁸	IV	Review of 100 consecutive pelvic fracture patients in an 11-month period to identify factors affecting mortality. The average ISS was 29.2 ± 12.9 . Fifty-two per cent were hypotensive at presentation. Fifty percent underwent angiography. A remarkable 27.2% false positive rate for DPL is reported in patients with large retroperitoneal haematoma's. ISS, head injury, hypotension at admission and blood transfusion requirement were associated with higher mortality.
Gordon 1983 ⁶²	IV	Case report of two patients with major pelvic fracture hemorrhage. Hemorrhage was arrested with angiography and embolisation of the internal iliac arteries.
Grimm 1998 ⁷⁶	III-3	In nine cadaveric specimens the true pelvic volume was assessed in an intact pelvic ring and disrupted pelvic ring with and without external fixation. Reduction of the pelvic ring with external fixation had little effect on volume and potential space for haematoma. External fixation did not contribute to control pelvic bleeding by generating pressure-induced tamponade. Theoretically, the beneficial effect of external fixation lies in the reapposition of tissue to allow clotting of disrupted veins and protection of clotted vessels from movement.
Hamill 2000 ¹⁷	III-3	Prospective review of 76 patients with major pelvic fractures and transfused more than six units of blood. Forty-four per cent of embolised patients had fracture patterns with major ligament disruptions, whereas 18% of embolised patients did not have fracture patterns that indicated major ligamentous disruption. The Young-Burgess classification was used. Need for embolisation correlated with more severe fracture pattern, but the relationship was not sufficient enough to warrant change to current indications for angiography.

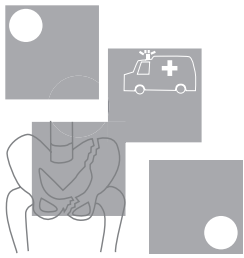
Author & year	Level of evidence	Finding
Hawkins 1970 ⁵⁷	III-3	A review from the early 1970s of 192 patients with pelvic fractures but focused on 35 patients who underwent exploratory laparotomy. Twenty laparotomies were preceded by DPL. Thirty had surgically controllable intra-peritoneal injuries. Non-therapeutic laparotomy rate was 15%. Mortality was 20%. Six patients who died required a mean transfusion requirement of 22.4 units of blood. No correlation between pelvic fracture pattern and the need for laparotomy. It is not clear, however, which classification was used. The authors report a dismal salvage rate of trying to surgically control retroperitoneal hemorrhage. However, if indications of intra-abdominal injuries requiring surgery are also present, the surgeon should still perform laparotomy.
Hehir 1990 ⁴⁰	III-2	Prospective review of 100 patients presenting with a chest injury and an AIS above 3. Reported interpretations of the first CXR were compared with chest injuries finally diagnosed. In 19 out of 77 surviving patients and 8 out of 17 non-surviving patients significant abnormalities were not diagnosed on the initial CXR.
Holting 1992 ⁶⁷	IV	Analysis of angiographic management of 20 patients with pelvic fractures and arterial bleeding. Angiography was introduced in the management when control of haemodynamic instability had failed. Aggressive volume resuscitation with or without laparotomy usually preceded angiography. Mean time to angiography was seven hours in survivors (n=9) and 21 hours for non-survivors (n=11).
Huang 1995 ⁵²	IV	Review of 43 patients, in which 18 DPLs and 25 FAST were performed separately. Sensitivity, specificity and accuracy were 100%, 40% and 66% for DPL and 95%, 50% and 84% for FAST.
Kam 1981 ³¹	IV	A description of angiographic findings in 63 pelvic fracture patients. The internal pudendal artery (27%) was the most frequent bleeding site identified, followed by the superior gluteal artery (25%). No correlation of angiographic findings to the mechanism of injury or fracture pattern was found, but this was demonstrated only by plain films of two cases.
Klein 1992 ²⁸	III-3	A review of 429 blunt pelvic trauma patients. The Kane modification of the Key and Conwell pelvic fracture classification was used. Posterior pelvic ring disruptions required significantly more blood transfusions in the first 24 hours, was associated with arterial injury requiring intervention, which was angiography and embolisation if no intra-abdominal injury requiring surgery was present. Also significantly increased mortality and associated injuries were seen in posterior ring disruptions.
Latenser 1991 ⁷²	III-3	Comparative study with historical control of 37 patients divided into two groups. In group 1 external fixation was not routinely used between 1981 and 1984. In group 2 external fixation was performed unless contra-indicated between 1985 and 1988. Groups matched well for age, sex, ISS and mechanism of injury. In group 1 60% were disabled for at least six months compared to 17% in group 2. Survival in group 1 was 83%, in group 2 100%. Hospital stay was decreased by 38% in group 2. These were significant differences.
Looser 1976 ³⁰	III-3	Retrospective review of 100 consecutive patient with violent pelvic trauma between 1970 and 1971. There were 70 associated injuries in group 1 and 125 associated injuries in group 2. Group 1 (57 patients) had purely anterior fractures and group 2 (43 patients) had purely posterior fractures. In group 1 30% had retroperitoneal bleeding compared to 83% in group 2.
Lu 2000 ³⁹	IV	One hundred trauma team activations in a level 1 trauma centre were analysed. The radiographer was present in 69% of cases on arrival of the patient. Median time to achieve shooting of the CXR was five minutes, with a range of two to 22 minutes. Together with other parameters this analysis provided a template to improve performance in early trauma management.
Mattox 1989 ⁸¹	II	Prospective -randomized study of 911 hypotensive patients randomly assigned to MAST and no-MAST groups. Groups were matched for age, sex, ISS and etiology of injury. MAST did not improve survival (31% mortality in MAST group and 25% in No-MAST group), increased pre-hospital time and most adversely affected outcome in cardiac and thoracic vascular injury.

Author & year	Level of evidence	Finding
Margolies 1972 ⁵⁸	IV	Case-series in which angiography with embolisation was used to control pelvic fracture haemorrhage. The authors attributed higher morbidity and mortality to late embolisation.
McKenney 1996 ⁵³	III-2	Prospective study in 200 patients with BAT. Ultrasound was initially performed and subsequently without knowledge of the US results, DPL or CT was performed. US sensitivity was 83%, specificity 100% and accuracy was 97% at predicting intra-abdominal injuries. Six injuries were missed, but only one was felt to be significant.
McMurtry 1980 ¹²	III-3	A review of 76 patients with combined anterior/posterior fractures. Their classification is not widely accepted. Forty-three had posterior ring disruption and a 100% increase in blood transfusion requirement and a 150% increase in mortality compared with historical controls. Open-technique DPL drove the treatment protocol in haemodynamically unstable patients. Positive results warranted laparotomy and negative results warranted angiography. Large arteries were surgically controlled and smaller arteries were embolised.
Moore 1981 ⁴⁷	IV	Case series in which the open DPL technique at the umbilical ring is described. Fewer complications were found.
Moreno 1986 ¹⁴	III-3	The study group consisted of 92 haemodynamically unstable pelvic fracture patients, indicated by requirement of more than 6 units of packed red cells. When applied, anti-shock trousers controlled pelvic bleeding in 71% of patients. External fixation was effective for hemorrhage control in 95% of cases. If external fixation and/or laparotomy failed, angiography was utilised. Overall mortality was 26%.
Moss 1996 ⁷⁴	III-3	A cadaveric study using a balloon in the true pelvis to measure volume. Open-book type pelvic ring disruptions were simulated by increasing pubic diastasis to specified distances and then measuring true pelvic volume. Varying sacroiliac joint and combined symphysis sacroiliac joint separations were also simulated. Changes in the true pelvic volume as a result of pelvic ring disruptions were much smaller than previously reported.
Mucha 1984 ⁵⁹	III-3	<p>Analysis of pelvic fracture management over a five-year period of 533 patients. Overall mortality was 6.4%. Based on the Key and Conwell classification 36% of fractures were considered complicated due to fracture pattern and, more often, associated injuries. Mean ISS was 35.8 and mortality of these patients, when haemodynamically unstable was 42%, compared to a 3.4% mortality in stable patients. Additionally there was significantly increased ISS and more severe pelvic fracture types in unstable patients.</p> <p>Angiography and embolisation was utilised in only 13 patients, of whom 4 had prior laparotomy, with an 86% success rate. In relation to pelvic fracture deaths the importance of associated injuries is stressed. Only in 12% of deaths was the pelvic fracture unquestionably the major cause. In 53% pelvic trauma played a contributing role and in 35% pelvic trauma was considered inconsequential.</p>
Lu 2000 ³⁹	IV	One hundred trauma team activations in a level 1 trauma centre were analysed. The radiographer was present in 69% of cases on arrival of the patient. Median time to achieve shooting of the CXR was five minutes, with a range of two to 22 minutes. Together with other parameters this analysis provided a template to improve performance in early trauma management.
Namm 1983 ⁴⁵	IV	A review of 102 patients, but is focused on a small series of 11 haemodynamically unstable patients. This group required increased blood transfusion requirements. Anti-shock trousers, external fixation and angiography and embolisation were very useful.
Nunes 2001 ⁴⁹	III-2	Prospective study of 147 patients after blunt and penetrating trauma who underwent US examination of the abdomen, followed by CT and/or laparotomy. Sensitivity, specificity and accuracy for predicting abdominal and pelvic injury were 57%, 99% and 95%. Repeat US examination decreased false negative rates by 50%. A learning curve was also observed, with 67% of the false negative findings occurring in the first three months of the 19-month study.

Author & year	Level of evidence	Finding
Palmer 1997 ⁸⁹	III-3	A prospective cohort study to assess the safety and efficacy of pelvic external fixators over a three-year period in 24 patients. All external fixators were applied within 6 hours of arrival. The complication rate was 47%, mostly due to poor pin positioning and pin site infection with skin necrosis. This interferes with subsequent management.
Panetta 1985 ¹³	III-2	Report of a protocolled treatment for pelvic fracture patients with blood transfusion requirements. The protocol involved angiographic embolisation to control pelvic bleeding once the abdomen was controlled by laparotomy, if necessary. Embolisation success rate was 87%. Three of the 11 deaths in the series did not respond to embolisation.
Perez 1998 ⁶⁰	IV	A review over a 10-year period in which 721 pelvic fracture patients were seen. Only eight underwent pelvic angiography. Bleeding pelvic vessels were identified in four patients (50% yield) and success rate of embolisation was 50%. Emphasis is placed on the ischaemic complications seen after embolisation and the safety of the technique is questioned.
Poole 1991 ⁷	III-3	A multivariate multiple regression analysis correlating outcome with ISS in patients with pelvic fractures. Two-hundred and thirty-six patients were reviewed. Mortality was 7.6%. Hemorrhage accounted for only 1 death. Analysis showed degree of pelvic fracture severity correlated with ISS, but death could not be predicted. Therefore associated injuries predicted outcome (mortality) following pelvic fractures.
Poole 1994 ²⁰	IV	Analysis of 90 unstable pelvic fracture patients of whom 66 underwent external fixation. Subsequently 10 of these 66 patients had internal fixation after external fixation had led to haemodynamic stability. Eighteen patients underwent pelvic angiography, revealing pelvic arterial bleeding in 33% of cases. Mortality was 16% in the angiography group.
Richardson 1982 ³	IV	Utilizing a graded approach to management of hemorrhage in 37 open pelvic fracture patients a 94.5% survival rate was achieved. The approach included wound packing, direct suturing, anti-shock trousers and hemipelvectomy (in two cases) for external control. For intrapelvic hemorrhage control anti-shock trousers, pelvic packing and angiographic embolisation was used.
Riemer 1993 ²⁵	III-2	Comparison of mortality in a group of 605 pelvic fracture patients from 1981 to 1988. After 1983 early external fixation as a resuscitative measure was introduced as part of an organized multidisciplinary protocol. From 1981 to 1988 mean ISS of pelvic fracture patients and blunt abdominal trauma patients did not change. As controls patients with blunt trauma, but without pelvic trauma were studied. As further controls head injured patients with pelvic fractures were compared with head injured patients without pelvic fractures. Mortality fell from 26% to 6% after 1983 in pelvic fracture patients. Mortality in head injured patients with pelvic fractures fell from 43% to 7 % after 1983. The organized protocol including external fixation reduced mortality.
Rothen-berger 1978 ^{2d}	IV	Review of 22 open pelvic fracture and 582 closed pelvic fracture patients. Mortality of open fractures was 50%, whereas in closed pelvic fractures mortality was 10.5%. The open pelvic fracture was the cause of death in 73% of patients, in closed pelvic fractures this was 30%.
Rothen-Berger 1978 ^{24d}	IV	A review of 604 patients, but is focused on the 72 who died. Of these 72 deaths, 71 had associated injuries, but in 36.1% death was entirely attributed to the pelvic fracture. In these pelvic fracture related deaths 69% died of hemorrhagic shock. Of the major pelvic vessel disruptions described, it is not clear which part is arterial and which part is venous.

Author & year	Level of evidence	Finding
Velmahos 2000 ⁴³	III-3	Retrospective review of utilisation of angiography and embolisation in 137 consecutive patients with blunt and penetrating intra- and retroperitoneal trauma. There were 71 blunt pelvic trauma cases. Most frequently the internal iliac was the embolised vessel (84%), followed by the superior gluteal artery (6%), internal pudendal artery (4%), lateral sacral artery (3%) and the obturator and iliolumbar arteries (1.5% each). Twenty-eight bilateral internal iliac embolisations took place without adverse sequelae.
Velmahos 2002 ⁴⁴	III-2	<p>Prospective safety and efficacy study of 100 patients with abdominal visceral organ injuries or major pelvic fractures sent for emergent or pre-emptive angiography and embolisation. The efficacy of AE was based on its ability to control bleeding radiographically and clinically; the safety of AE was determined by the complications related to transport, vascular access, catheter insertion, contrast administration, and tissue necrosis following interruption of blood supply to organs.</p> <p>Of 100 consecutive patients evaluated by angiography for bleeding from major pelvic fractures (65) or solid visceral organ injuries (35), 80 were embolised. AE was effective and safe in 95% and 94% respectively of 80 patients who were embolised. Three independent factors were predictive of bleeding identified on angiography: age older than 55 years, absence of long-bone fractures, and "emergent" angiography. The presence of all three independent predictors was associated with a 95% probability of bleeding.</p>
Vrahas 1998 ⁸⁶	III-3	Cadaveric biomechanical study in which three methods of internal fixation and external fixation were analyzed and compared. Open internal antero-posterior fixation provided the greatest pelvic stability expansion overall, but external fixation proved the most practical method in the resuscitation situation.
Waikukul 1999 ⁷³	III-1	Prospective comparison with randomisation of 112 patients with unstable pelvic fractures. Group 1 (n=70) was submitted to conventional management without early external fixation. Group 2 (n=42) received early orthopaedic consultation and early external fixation. Baseline parameters were similar in both groups. Blood transfusion, post-operative pain and skeletal deformity were less in group 2.





Pelvic sheeting

For rotationally unstable pelvic fractures: Open-book, Vertical Shear, Lateral Compression type III or Combined Mechanism fractures

1

Place folded bed sheet underneath the patient between iliac crests and greater trochanters.



2

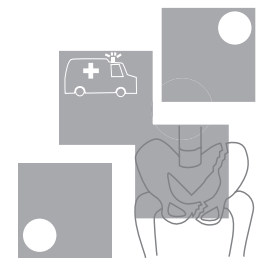
With two trauma team members cross the sheet across the symphysis and pull the sheet firmly so it tightly fits around and stabilises the pelvis.



3

A third person should clamp the sheet at the four points shown (away from laparotomy / angiograph access points).





References

- 1 Trunkey DD, Chapman MW, Lim RC Jr, Dunphy JE 1974, Management of pelvic fractures in blunt trauma injury, *Journal of Trauma-Injury Infection & Critical Care* 14(11):912-23.
- 2 Rothenberger D, Velasco R, Strate R, Fischer RP, Perry JF Jr 1978, Open pelvic fracture: a lethal injury, *Journal of Trauma-Injury Infection & Critical Care* 18(3):184-7.
- 3 Richardson JD, Harty J, Amin M, Flint LM 1982, Open pelvic fractures, *Journal of Trauma-Injury Infection & Critical Care* 22(7):533-8.
- 4 Naam NH, Brown WH, Hurd R, Burdge RE, Kaminski DL 1983, Major pelvic fractures, *Archives of Surgery* 118(5):610-6.
- 5 Evers B, Cryer HM, Miller F 1989, Pelvic Fracture Haemorrhage, *Archives of Surgery* 1989;124:422-4.
- 6 Cryer HM, Miller FB, Evers BM, Rouben LR, Seligson DL 1988, Pelvic fracture classification: correlation with hemorrhage, *Journal of Trauma-Injury Infection & Critical Care* 28(7):973-80.
- 7 Poole GV, Ward EF, Muakkassa FF, Hsu HS, Griswold JA, Rhodes RS 1991, Pelvic fracture from major blunt trauma. Outcome is determined by associated injuries, *Annals of Surgery* 213(6):532-8; discussion 538-9.
- 8 Gilliland MD, Ward RE, Barton RM, Miller PW, Duke JH 1982, Factors affecting mortality in pelvic fractures, *Journal of Trauma-Injury Infection & Critical Care* 22(8):691-3.
- 9 Tile M 1988, Pelvic ring fractures: Should they be fixed? *Journal of Bone & Joint Surgery – British Volume Vol 70(1)*; 34-37.
- 10 Eastridge BJ, Burgess AR 1997, Pedestrian pelvic fractures: 5-year experience of a major urban trauma center, *Journal of Trauma-Injury Infection & Critical Care* 42(4):695-700, 1997 Apr.
- 11 Bassam D, Cephas GA, Ferguson KA, Beard LN, Young JS 1998, A protocol for the initial management of unstable pelvic fractures, *American Surgeon* 64(9):862-7.
- 12 McMurtry R, Walton D, Dickinson D, Kellam J, Tile M 1980, Pelvic disruption in the polytraumatized patient: a management protocol, *Clinical Orthopaedics & Related Research* (151):22-30.
- 13 Panetta T, Scalfani S, Goldstein AS, Phillips TF, Shaftan GW 1985, Percutaneous transcatheter embolisation for massive bleeding from pelvic fractures, *Journal of Trauma-Injury Infection & Critical Care* 1985;25:1021-9.
- 14 Moreno C, Moore EE, Rosenberger A, Cleveland HC 1986, Hemorrhage associated with major pelvic fracture: a multispecialty challenge, *Journal of Trauma-Injury Infection & Critical Care* 26(11):987-94, 1986 Nov.
- 15 Flint L, Babikian G, Anders M, Rodriguez J, Steinberg S 1990, Definitive control of mortality from severe pelvic fracture, *Annals of Surgery* 211(6):703-6; discussion 706-7.
- 16 Gruen GS, Leit ME, Gruen RJ, Peitzman AB 1994, The acute management of hemodynamically unstable multiple trauma patients with pelvic ring fractures, *Journal of Trauma-Injury Infection & Critical Care* 36(5):706-11; discussion 711-3.
- 17 Hamill J, Holden A, Paice R, Civil I 2000, Pelvic fracture pattern predicts pelvic arterial haemorrhage, *Australian & New Zealand Journal of Surgery* 70(5):338-43.
- 18 Ertel W, Keel M, Eid K, Platz A, Trentz O 2001, Control of severe hemorrhage using C-clamp and pelvic packing in multiply injured patients with pelvic ring disruption [see comment], *Journal of Orthopaedic Trauma* 15(7):468-74.
- 19 Eastridge BJ, Starr A, Minei JP, O'Keefe GE, Scalea TM 2002, The importance of fracture pattern in guiding therapeutic decision-making in patients with hemorrhagic shock and pelvic ring disruptions, *Journal of Trauma-Injury Infection & Critical Care* 53(3):446-50; discussion 450-1.
- 20 Poole GV, Ward EF 1994, Causes of mortality in patients with pelvic fractures, *Orthopedics* 17(8):691-6.

- 21 Duane TM, Tan BB, Golay D, Cole FJ Jr, Weireter LJ Jr, Britt LD 2002, Blunt trauma and the role of routine pelvic radiographs: a prospective analysis, *Journal of Trauma-Injury Infection & Critical Care* 53(3):463-8.
- 22 Grant P 1990, The diagnosis of pelvic fractures by springing, *Archives of Emergency Medicine* 1990;7(3):178-82.
- 23 Dalal SA, Burgess AR, Siegel JH, Young JW, Brumback RJ, Poka A, et al 1989, Pelvic fracture in multiple trauma: classification by mechanism is key to pattern of organ injury, resuscitative requirements, and outcome, *Journal of Trauma-Injury Infection & Critical Care* 29(7):981-1000; discussion 1000-2, 1989 Jul.
- 24 Rothenberger DA, Fischer RP, Strate RG, Velasco R, Perry JF Jr 1978, The mortality associated with pelvic fractures, *Surgery* 84(3):356-61.
- 25 Riemer BL, Butterfield SL, Diamond DL, Young JC, Raves JJ, Cottingham E et al 1993, Acute mortality associated with injuries to the pelvic ring: the role of early patient mobilization and external fixation, *Journal of Trauma-Injury Infection & Critical Care* 35(5):671-5; discussion 676-7.
- 26 Poole GV, Ward EF, Griswold JA, Muakkassa FF, Hsu HS 1992, Complications of pelvic fractures from blunt trauma, *American Surgeon* 58(4): 225-31.
- 27 Burgess AR, Tile M 1991, Fractures of the pelvis. In: Rockwood C, Green D, editors, *Fractures in Adults*, Philadelphia: JB Lippincott; p.1399-442.
- 28 Klein SR, Saroyan RM, Baumgartner F, Bongard FS 1992, Management strategy of vascular injuries associated with pelvic fractures, *Journal of Cardiovascular Surgery* 33(3):349-57.
- 29 McMurtry RY 1989, Pelvic fractures and dislocations. (i) Initial assessment and management, *Current Orthopaedics* Vol 3(4); 233-227, 1989
- 30 Looser KG, Crombie HD Jr 1976, Pelvic fractures: an anatomic guide to severity of injury, Review of 100 cases, *American Journal of Surgery* 132(5):638-42.
- 31 Kam J, Jackson H, Ben-Menachem Y 1981, Vascular injuries in blunt pelvic trauma, *Radiologic Clinics of North America* Vol 19(1); 171-186).
- 32 Resnik CS, Stackhouse DJ, Shanmuganathan K, Young JW 1992, Diagnosis of pelvic fractures in patients with acute pelvic trauma: efficacy of plain radiographs, *AJR American Journal of Roentgenology* 158(1):109-12.
- 33 Robertson D, Sutherland C, Chan B, Hodge J, Scott W, Fishman E 1995, Depiction of pelvic fractures using 3D volumetric holography: comparison of plain X-ray and CT, *J Comput Assist Tomogr* 1995;19(6):967-74.
- 34 Ben-Menachem Y, Coldwell DM, Young JW, Burgess AR 1991, Hemorrhage associated with pelvic fractures: causes, diagnosis, and emergent management, [Review] [50 refs], *AJR American Journal of Roentgenology* 157(5):1005-14.
- 35 Kellam JF, Trafton PG. Fractures of the Pelvic Ring. In: Browner BD, Jupiter J, Levine A, Trafton PG, editors 1992, *Skeletal Trauma*, Volume 1 ed. Philadelphia: WB Saunders; 1992. p. 849-97.
- 36 American College of Surgeons Committee on Trauma 1997, *Advanced Trauma Life Support for Doctors* (6th Edition).
- 37 Ali J, Howard M, Williams J 2002, Is attrition of advanced trauma life support acquired skills affected by trauma patient volume? *American Journal of Surgery* 183(2):142-5.
- 38 American College of Surgeons 1997, *Advanced Trauma life support for Doctors Instruction Course Manual Book 1*, First Impression: USA 1997.
- 39 Lu W, Kolkman K, Seger M, Sugrue M 2000, An evaluation of trauma team response in a major trauma hospital in 100 patients with predominantly minor injuries, *ANZ Journal of Surgery* 70(5):329-32.
- 40 Hehir MD, Hollands MJ, Deane SA 1990, The accuracy of the first chest X-ray in the trauma patient, *Australian & New Zealand Journal of Surgery* 60(7):529-32.
- 41 Agolini SF, Shah K, Jaffe J, Newcomb J, Rhodes M, Reed JF, III 1997, Arterial embolisation is a rapid and effective technique for controlling pelvic fracture hemorrhage [see comment], *Journal of Trauma-Injury Infection & Critical Care* 43(3):395-9.
- 42 Velmahos GC, Chahwan S, Hanks SE, Murray JA, Berne TV, Asensio J, et al 2000, Angiographic embolisation of bilateral internal iliac arteries to control life-threatening hemorrhage after blunt trauma to the pelvis, *American Surgeon* 66(9):858-62.

- 43 Velmahos GC, Chahwan S, Falabella A, Hanks SE, Demetriades D 2000, Angiographic embolisation for intraperitoneal and retroperitoneal injuries, *World Journal of Surgery* 24(5):539-45.
- 44 Velmahos GC, Toutouzas KG, Vassiliu P, Sarkisyan G, Chan LS, Hanks SH, et al 2002, A prospective study on the safety and efficacy of angiographic embolisation for pelvic and visceral injuries, *Journal of Trauma-Injury Infection & Critical Care* 53(2):303-8; discussion 308.
- 45 Namm NHBW, Hurd R, Burdge R, Kaminski D 1983, Major pelvic fractures, *Archives of Surgery* 118:610-6.
- 46 Sugrue M, Seger M, Gunning K, Sloane D, Deane S 1995, A modified combination technique for performing diagnostic peritoneal lavage, *ANZ Journal of Surgery* 1995;65:604-6.
- 47 Moore JB, Moore EE, Markovchick VJ, Rosen P 1981, Diagnostic peritoneal lavage for abdominal trauma: Superiority of the open technique at the infraumbilical ring, *Journal of Trauma-Injury Infection & Critical Care* Vol 21(7); 570-572.
- 48 McKenney M, Lentz K, Nunez D, Sosa JL, Sleeman D, Axelrad A et al 1994. Can ultrasound replace diagnostic peritoneal lavage in the assessment of blunt trauma? [see comment], *Journal of Trauma-Injury Infection & Critical Care* 37(3):439-41.
- 49 Nunes LW, Simmons S, Hallowell MJ, Kinback R, Trooskin S, Kozar R 2001, Diagnostic performance of trauma US in identifying abdominal or pelvic free fluid and serious abdominal or pelvic injury, *Academic Radiology* 8(2):128-36.
- 50 Rozycki GS, Newman PG 1999, Surgeon-performed ultrasound for the assessment of abdominal injuries, *Advances in Surgery* 33:243-59.
- 51 Rozycki GS, Ochsner MG, Feliciano DV, Thomas B, Boulanger BR, Davis FE et al 1998, Early detection of hemoperitoneum by ultrasound examination of the right upper quadrant: a multicenter study, *Journal of Trauma-Injury Infection & Critical Care* 45(5):878-83.
- 52 Huang J, Fang J, Chen R 1995, Diagnosis of intraperitoneal injuries in patients with pelvic fractures, *Changgeng Yi Xue Za Zhi* 1995;18(2):154-9.
- 53 McKenney KL, McKenney MG, Nunez DB, McDowell L, Martin L 1996, Interpreting the trauma ultrasound: Observations in 62 positive cases, *Emergency Radiology* Vol 3(3); 113-117.
- 54 Ballard RB, Rozycki GS, Newman PG, Cubillos JE 1999, Salomone JP, Ingram WL et al, An algorithm to reduce the incidence of false-negative FAST examinations in patients at high risk for occult injury, Focused Assessment for the Sonographic Examination of the Trauma patient, *Journal of the American College of Surgeons* 189(2):145-50; discussion 150-1.
- 55 Bode PJ, Niezen RA, Van Vugt AB, Schipper J 1993, Abdominal ultrasound as a reliable indicator for conclusive laparotomy in blunt abdominal trauma [see comment], *Journal of Trauma-Injury Infection & Critical Care* 34(1):27-31, 1993 Jan.
- 56 Ballard RB, Rozycki GS, Newman PG, Cubillos JE, Salomone JP, Ingram WL et al 1999, An algorithm to reduce the incidence of false-negative FAST examinations in patients at high risk for occult injury, *Journal of the American College of Surgeons* Vol 189(2); 145-151.
- 57 Hawkins L, Pomerantz M, Eisman B 1970, Laparotomy at time of pelvic fracture, *Journal of Trauma-Injury Infection & Critical Care* 1970;10:619-23.
- 58 Margolies MN, Ring E, Waltman AC, Kerr W, Baum F 1972, Arteriography in the management of haemorrhage from pelvic fractures, *New England Journal of Medicine* 287:317-21.
- 59 Mucha P, Jr., Farnell MB 1984, Analysis of pelvic fracture management, *Journal of Trauma-Injury Infection & Critical Care* 24(5):379-86.
- 60 Perez J, Hughes P, Bowers S 1998, Angiographic embolisation in pelvic fracture, *Injury* 29:187-91.
- 61 Stephen DJ, Kreder HJ, Day AC, McKee MD, Schemitsch EH, ElMaraghy A, et al 1999, Early detection of arterial bleeding in acute pelvic trauma, *Journal of Trauma-Injury Infection & Critical Care* 47(4):638-42.
- 62 Gordon RL, Fast A, Aner H 1983, Control of massive retroperitoneal bleeding associated with pelvic fractures by angiographic embolisation, *Israel Journal of Medical Sciences* Vol 19(2);185-188.
- 63 Clarke JR, Trooskin SZ, Doshi PJ, Greenwald L, Mode CJ 2002, Time to laparotomy for intra-abdominal bleeding from trauma does affect survival for delays up to 90 minutes, *Journal of Trauma-Injury Infection & Critical Care* 52(3):420-5.
- 64 Van UH, Perlberger RR, Muller H 1978, Selective arterial embolisation for control of traumatic pelvic hemorrhage, *Surgery* 83(2):133-7.

- 65 Slatis P, Huittinen VM 1972, Double vertical fractures of the pelvis, *Acta Chirurgica Scandinavica* 1972;138:799-802.
- 66 Huittinen V, Slatis P. Post mortem angiography and dissection of the hypogastric artery in pelvic fractures, *Surgery* 1973;73:454-62.
- 67 Holting T, Buhr HJ, Richter GM, Roeren T, Friedl W, Herfarth C 1992, Diagnosis and treatment of retroperitoneal hematoma in multiple trauma patients, *Archives of Orthopaedic & Trauma Surgery* 111(6):323-6.
- 68 Flint LM, Brown A, Richardson JD, Polk HC Jr 1979, Definitive control of bleeding from severe pelvic fractures, *Annals of Surgery* 89:709-16.
- 69 Mucha JP, Welch TJ 1988, Hemorrhage in major pelvic fractures, *Surgical Clinics of North America* Vol 68(4); 757-773.
- 70 Kellam JF 1989, The role of external fixation in pelvic ring disruptions, *Clinical Orthopaedics & Related Research* 1989;241:66-82.
- 71 Broos P, Vanderschot P, Craninx L, Rommens P 1992, The operative treatment of unstable pelvic ring fractures, *International Surgery* 77(4):303-8, 1992 Oct;-Dec.
- 72 Latenser BAGL, Tarver A 1991, Improved outcome with early fixation of skeletally unstable pelvic fractures, *Journal of Trauma-Injury Infection & Critical Care* 31:28-31.
- 73 Waikukul S, Harnroonroj T, Vanadurongwan V 1999, Immediate stabilisation of unstable pelvic fractures vs delayed stabilisation, *Journal of the Medical Association of Thailand* 82(7):637-42.
- 74 Moss MC, Bircher MD 1996, Volume changes within the true pelvis during disruption of the pelvic ring – Where does the haemorrhage go? *Injury* Vol 27(SUPPL 1).
- 75 DiGiacomo JC, Bonadies J, Cole F, Diebel L, Hoff W, Holevar M et al 2001, Practice Management Guidelines for Haemorrhage in Pelvic Fracture, *EAST*.
- 76 Grimm M, Vrahas M, Thomas K 1998, Pressure-volume characteristics of the intact and disrupted pelvic retroperitoneum, *Journal of Trauma-Injury Infection & Critical Care* 44:454-9.
- 77 Ghanayem AJ, Wilber JH, Lieberman JM, Motta AO 1995, The effect of laparotomy and external fixator stabilisation on pelvic volume in an unstable pelvic injury, *Journal of Trauma-Injury Infection & Critical Care* 38(3):396-400; discussion 400-1.
- 78 Routt ML, Jr., Simonian PT, Ballmer F 1995, A rational approach to pelvic trauma, Resuscitation and early definitive stabilisation, *Clinical Orthopaedics & Related Research* (318):61-74.
- 79 Fleming W, Bowen J 1973, Control of hemorrhage in pelvic crush injuries, *Journal of Trauma-Injury Infection & Critical Care* 1973;13:567-70.
- 80 Matta JM 1996, Indications for anterior fixation of pelvic fractures, *Clinical Orthopaedics & Related Research* (329):88-96.
- 81 Mattox KL, Bickell WH, Pepe PE, Mangelsdorff AD, Prospective randomized evaluation of antishock MAST in post-traumatic hypotension, *Journal of Trauma-Injury Infection & Critical Care* 26(9):779-86, 1986 Sep.
- 82 Ben-Menachem Y, Handel SF, Ray RD, Childs III TL 1985, Embolisation procedures in trauma; *The pelvis. Seminars in Interventional Radiology* Vol 2(2);158-181.
- 83 Kaufman J, Waltman A 1997, Angiographic management of haemorrhage in pelvic fracture, *Abrams Angiography- Interventional Radiology*, Volume III. 4th ed. Little, Brown and Co p.869-83.
- 84 Hoffer EK 1999, Interventional angiography for treatment of hemorrhage in pelvic trauma, *Emergency Radiology* Vol 6(4); 216-226, 1999
- 85 Garcia J, Doblare M, Seral B, Seral F, Palanca D 2000, Three dimensional finite element analysis of several internal and external pelvis fixations, *Journal of Biomechanical Engineering* 122:516-22.
- 86 Vrahas M, Wilson SC, Cummings P, Paul E 1998, Comparison of fixation methods for preventing pelvic ring expansion, *Orthopaedics* 21:285-9.
- 87 Ghanayem AJ, Stover MD, Goldstein JA, Bellon E, Wilber JH 1995, Emergent treatment of pelvic fractures, Comparison of methods for stabilisation *Clinical Orthopaedics & Related Research* (318):75-80.
- 88 Simpson T, Kreig J, Heuer F, Bottlang M 2002, Stabilisation of pelvic ring disruptions with a circumferential sheet, *Journal of Trauma-Injury Infection & Critical Care* 52:158-61.
- 89 Palmer S, Fairbank A, Bircher M 1997, Surgical complications and implications of external fixation for pelvic fractures, *Injury* 28:649-53.
- 90 Ganz R 1991, The antishock pelvic clamp, *Clinical Orthopaedics & Related Research* 267:71-8.

- 91 Simonian PT, Routt ML Jr, Harrington RM, Tencer AF 1995, Anterior versus posterior provisional fixation in the unstable pelvis. A biomechanical comparison, *Clinical Orthopaedics & Related Research* (310):245-51.
- 92 Rozycki GS, Ballard RB, Feliciano DV, Schmidt JA, Pennington SD 1998, Surgeon-performed ultrasound for the assessment of truncal injuries: lessons learned from 1540 patients, *Annals of Surgery* 228(4):557-67.

